

CECÍLIA FERNANDA FARIAS CRAVEIRO

**REPRODUÇÃO DO CAMARÃO SETE-BARBAS *Xiphopenaeus kroyeri*
(HELLER 1862): UMA NOVA ABORDAGEM PARA ESTUDOS DO
DESENVOLVIMENTO OVARIANO DE CAMARÕES PENEÍDEOS**

RECIFE,

2022



UNIVERSIDADE FEDERAL RURAL DE PERNAMBUCO
PRÓ-REITORIA DE PESQUISA E PÓS-GRADUAÇÃO
PROGRAMA DE PÓS-GRADUAÇÃO EM RECURSOS PESQUEIROS E AQUICULTURA

REPRODUÇÃO DO CAMARÃO SETE-BARBAS *Xiphopenaeus kroyeri*
(HELLER 1862): UMA NOVA ABORDAGEM PARA ESTUDOS DO
DESENVOLVIMENTO OVARIANO DE CAMARÕES PENEÍDEOS

Cecília Fernanda Farias Craveiro

Trabalho de tese a ser julgado pelo Programa de Pós-Graduação em Recursos Pesqueiros e Aquicultura da Universidade Federal Rural de Pernambuco como exigência para obtenção do título de doutor.

Prof. Dr. Silvio Ricardo Maurano Peixoto
Orientador

Prof^a. Dr^a. Roberta Borda Soares
Coorientadora

RECIFE,
novembro/2022

UNIVERSIDADE FEDERAL RURAL DE PERNAMBUCO
PRÓ-REITORIA DE PESQUISA E PÓS-GRADUAÇÃO
PROGRAMA DE PÓS-GRADUAÇÃO EM RECURSOS PESQUEIROS E AQUICULTURA

REPRODUÇÃO DO CAMARÃO SETE-BARBAS *Xiphopenaeus kroyeri*
(HELLER 1862): UMA NOVA ABORDAGEM PARA ESTUDOS DO
DESENVOLVIMENTO OVARIANO DE CAMARÕES PENEÍDEOS

Cecília Fernanda Farias Craveiro

Trabalho de tese para obtenção do título
de doutor em Recursos Pesqueiros e
Aquicultura realizado em 29/11/2022
pela seguinte Banca Examinadora:

Prof. Dr. Silvio Ricardo Maurano Peixoto (Orientador)
Universidade Federal Rural de Pernambuco - UFRPE

Prof. Dr. Ronaldo Olivera Cavalli (Membro Titular Externo)
Universidade Federal do Rio Grande - FURG

Prof. Dr. Alex Souza Lira (Membro Titular Externo)
Universidade Federal de Sergipe - UFS

Dra. Mariana Gomes do Rêgo (Membro Titular Externo)
Departamento de Medicina Veterinária - (PNPD/CAPES)
Universidade Federal Rural de Pernambuco – UFRPE

Profa. Dra Renata Shinozaki Mendes (Membro Titular interno)
Departamento de Pesca e Aquicultura - DEPAq
Universidade Federal Rural de Pernambuco - UFRPE

Prof. Dr. Paulo Guilherme Vasconcelos de Oliveira (Membro Suplente Interno)
Departamento de Pesca e Aquicultura - DEPAq
Universidade Federal Rural de Pernambuco - UFRPE

Dr. Santiago Hamilton (Membro Suplente Externo)
Biociência Animal - (PNPD/CAPES)
Universidade Federal Rural de Pernambuco - UFRPE

Dados Internacionais de Catalogação na Publicação
Universidade Federal Rural de Pernambuco
Sistema Integrado de Bibliotecas
Gerada automaticamente, mediante os dados fornecidos pelo(a) autor(a)

C898r Craveiro, Cecília Fernanda Farias
Reprodução do camarão Sete-barbas *Xiphopenaeus kroyeri* (HELLER 1862): uma nova abordagem para estudos do desenvolvimento ovariano de camarões peneídeos / Cecília Fernanda Farias Craveiro. - 2022.
106 f. : il.

Orientador:
Silvio Peixoto.
Coorientador:
Roberta Borda
Soares. Inclui referências e apêndice(s).

Tese (Doutorado) - Universidade Federal Rural de Pernambuco, Programa de Pós-Graduação em Recursos Pesqueiros e Aquicultura, Recife, 2022.

1. Histologia. 2. Manejo. 3. Maturação. 4. Morfologia. 5. Maturidade ovariana. I. Peixoto, Silvio, orient. II. Soares, Roberta Borda, coorient. III. Título

CDD 639.3

Dedicatória

Dedico esta pesquisa à minha amada filha, Marina Craveiro Soares, por todas as horas de lazer em que abdiquei da companhia dela para me dedicar a este trabalho de tese!

Agradecimentos

Primeiramente a Deus, por estar presente em todos os momentos da minha vida;

Ao meu pai amado, Marcos André Craveiro Duarte, que me ensina diariamente o significado das palavras perseverança, força de vontade e luta. À minha mãe amada, Edna Maria Craveiro Farias, que me ensina diariamente o que é ter fé e amor incondicional. Aos meus irmãos, em especial ao meu irmão mais velho, André Filipe, por ter sido sempre um exemplo para mim sobretudo no âmbito dos estudos.

À minha filha, Marina, por ser sempre o motivo dos meus melhores momentos, melhores risadas, por despertar o melhor de mim e por sempre me inspirar a ser a melhor versão de mim mesma. Você é TUDO para mamãe! Te amo, filha!

À Eliane Ventura e Marcelo Soares por sempre me incentivarem e me apoiarem ao longo de toda a minha trajetória acadêmica. Obrigada por tudo!

Agradeço a todos os meus amigos, colegas, professores da graduação e da pós-graduação que me inspiraram, foram meus mentores e influenciaram a minha vida de modo definitivo. Meu agradecimento especial ao Prof. Dr. Silvio Peixoto e Prof^a. Roberta Soares por sempre extraírem o melhor do meu potencial, pelo carinho e apoio nos momentos mais difíceis que passei ao longo dessa trajetória acadêmica, pela amizade e principalmente pelos ensinamentos que levarei para o resto da minha vida. Agradeço muito a oportunidade que tive em ser orientada por vocês!

Aos membros da banca que são pesquisadores que eu admiro muito. Foi uma honra receber seus conselhos e sugestões. Obrigada por tudo!

Ao Prof. Dr. Emanuell Felipe Beserra da Silva pelas contribuições e por todos os ensinamentos pessoais e profissionais, mas principalmente por ter me dado a honra de trabalhar no projeto que deu origem a este trabalho de tese.

Aos pescadores de camarões de Lucena, Paraíba, em especial ao pescador Severino. Obrigado pela inspiração e por terem me ensinado a amar a pesca de camarão! A todos os pescadores artesanais, que apesar da dificuldade enfrentada pela atividade, pela falta de incentivo de políticas públicas que os apoiem, exercem esta atividade com toda dedicação e paixão. Meu mais sincero respeito a todos vocês!

A minha amiga querida Larissa Bacelar, parceira de todas as horas, principalmente nas horas mais difíceis, sem a qual eu JAMAIS conseguiria finalizar este trabalho. Obrigada por tudo, Laris! Serei eternamente GRATA!

Ao meu amigo querido Hildemário Castro, que foi meu porto seguro no meio do caos. Obrigada pelo carinho, pela dedicação, companheirismo e incentivo principalmente nas horas mais difíceis! Só Deus sabe o que passamos pra finalizar essa quantidade absurda de amostras!! Sua amizade foi muitas vezes o meu combustível para lidar com as dificuldades! Serei eternamente GRATA!

Aos amigos Luquinhas e Yas, por ajudarem muito nas triagens das amostras. Vocês são de uma generosidade que nem sei descrever! Obrigada! Ao meu amigo querido Paulo Almeida, por ter sido meu grande conselheiro, pela ajuda nas intermináveis dúvidas durante os últimos seis anos de pós-graduação.

À Prof^a. Dr^a. Flávia Lucena Frédou e ao Prof. Dr. Thierry Frédou por cederem o laboratório Bioimpact para análise do trabalho, pelas conversas no momento de descontração e ensinamentos valiosos. À família Bioimpact por serem tão generosos, em especial aos amigos Alex, Nolé, Ray, Andrey, Rafa, Ann e Thaisa por estarem sempre disponíveis para ajudar e me garantirem ótimas risadas! Obrigada a Itala pela amizade e ajuda na parte final das amostras, principalmente durante minha gravidez.

Ao amigo Santiago Hamilton (Santi) por ter sido sempre um grande incentivador nas horas difíceis e nas horas alegres. Obrigada pelo carinho e amizade!

Aos amigos dos Laboratórios LEP e LOP, em especial ao Prof. Dr. Paulo Oliveira (Paulinho) e Prof Fábio Hazin (*in memoriam*), por terem sido tão generosos cedendo o laboratório e equipamentos para a realização desta pesquisa.

Ao Prof. Dr. Ronaldo Olivera Cavalli que me ofereceu a primeira oportunidade de bolsa PIBIC no Laboratório de Piscicultura marinha da UFRPE, onde eu aprendi a amar a pesquisa e tive a oportunidade de conhecer, me espelhar, me inspirar e aprender muito com ele ao longo da minha graduação. Meu muito obrigado também aos amigos queridos do LPM: Lelis, Narigones, Regi, Lari girl, Gabris e Barbis!! Vocês são mil!!

À coordenação de Aperfeiçoamento de Pessoal de Nível Superior (Capes), pela concessão da bolsa de doutorado ao longo desses quatro anos.

Ao Conselho Nacional de Desenvolvimento Científico e Tecnológico (CNPq) por ter financiado os projetos de pesquisa.

A todos familiares, amigos e colegas, que não foram citados aqui, mas que de alguma forma me apoiaram durante a minha trajetória acadêmica.

Muito obrigada!

Resumo

As mudanças morfológicas durante o desenvolvimento ovariano de *Xiphopenaeus kroyeri* foram avaliadas a fim de estabelecer um modelo para melhor compreender a dinâmica reprodutiva de camarões peneídeos. Um total de 1289 fêmeas foram coletadas através da pesca artesanal em Lucena, Paraíba, Brasil. As fêmeas foram investigadas para diferentes aspectos reprodutivos: no capítulo 1, a oogênese foi classificada em seis fases distintas: ovócitos cromatina nucleolar, ovócitos cromatina perinucleolar, ovócitos em vitelogênese primária, ovócitos em vitelogênese secundária, ovócitos maduros e ovócitos atrésicos. As observações histoquímicas sugeriram um aumento progressivo das proteínas e polissacarídeos neutros em ovócitos vitelogênicos até seu estágio final de maturação. As células foliculares compõem o complexo folicular, formando um epitélio externo aos ovócitos vitelogênicos, e provavelmente estão envolvidas na transferência de proteínas durante o processo de maturação. Foram identificadas vesículas de colágeno e glicoproteínas no citoplasma de ovócitos maduros. No capítulo II, dois métodos de análise macroscópica dos ovários foram testados quanto a precisão no estabelecimento dos estágios de maturação em comparação com a análise histológica, bem como as possíveis implicações na determinação da época de desova. Um método avaliou o estágio de maturação pela observação do ovário através do exoesqueleto com a ajuda de luz artificial, enquanto no outro foi avaliado macroscopicamente a partir da extração do ovário fresco, morfologia e aspecto do tecido que reveste o ovário. O segundo método mostrou maior concordância com a análise histológica do que o primeiro, destacando a importância de observar as características morfológicas de uma fêmea recém-capturada, uma vez que a coloração dos ovários varia com o tempo. Os dois métodos foram eficientes na identificação do estágio maturo, sugerindo que ambos podem ser utilizados no manejo de reprodutores em cativeiro. O agrupamento dos estágios desovado e de repouso em um único estágio pode ser considerado um grande problema, pois apresentam características e interpretações opostas do ponto de vista histológico, resultando em erros nas estimativas da época de desova. No capítulo 3, identificamos seis estágios de desenvolvimento ovariano. Os estágios desovado e de repouso, que são comumente agrupados em estudos reprodutivos de camarões peneídeos, foram separados pela primeira vez. Observamos vesículas acumuladas no citoplasma de ovócitos maduros. A análise histológica mostrou ovócitos com desenvolvimento síncrono apresentando desova total. O comprimento médio na maturidade (CC_{50}) para as fêmeas foi de 1,3 cm. O ciclo reprodutivo foi classificado como sazonal com maior maturidade ovariana e índice gonadossomático de outubro a março. O pico de desova ocorre durante o período de maior pluviosidade, com uma porcentagem maior de fêmeas desovadas. Os resultados contribuem para o conhecimento atual sobre a morfologia ovariana, processo de maturação podendo ser úteis para o manejo sustentável da pesca comercial do *Xiphopenaeus kroyeri* e o desempenho reprodutivo de camarões peneídeos em cativeiro.

Palavras-chave: histologia, manejo, maturação, morfologia, maturidade ovariana.

Abstract

The morphological changes during ovarian development of *Xiphopenaeus kroyeri* were evaluated in order to establish a model to better understanding their reproductive dynamics. A total of 1,289 females of *Xiphopenaeus kroyeri* were collected through artisanal fisheries in Lucena, Paraíba, Brazil. Females were investigated in relation to different reproductive aspects: in chapter 1, the oogenesis was classified into six distinct phases: chromatin nucleolar oocytes, chromatin perinucleolar oocytes, oocytes in primary vitellogenesis, oocytes in secondary vitellogenesis, mature oocytes, and atretic oocytes. Histochemical observations suggested a progressive increase of the proteins and neutral polysaccharides in vitellogenic oocytes until their final maturation stage. Follicular cells composed the follicular complex forming an external epithelium in vitellogenic oocytes, and are probably involved in protein transfer during ovarian maturation process. Collagen and glycoprotein vesicles were also identified in the cytoplasm of mature oocytes. In chapter II, two methods of macroscopic analysis of the ovaries were tested for accuracy in establishing maturation stages compared to histological analysis, as well as possible implications in determining the spawning season. One method evaluated the maturation stage was assessed by observing the ovary through the exoskeleton with the help of artificial light, while the other was evaluated macroscopically from the extraction of the fresh ovary, morphology and appearance of the tissue lining the ovary. The second method showed greater agreement with the histological analysis than the first method, emphasizing the importance of observing the morphological characteristics of a freshly caught female, since the staining of the ovaries tends to vary over time. Both methods were efficient in identifying the ripe stage, suggesting that both can be used in the management of captive broodstock. The grouping of the spent and resting stages into a single stage can be considered a major problem, because they present characteristics and opposite interpretations from the histological point of view, resulting in serious problems in the estimates of spawning season. In chapter 3, we identified six stages of ovarian development, based on macroscopic and histological analysis: immature, early developing, advanced developing, ripe, spent, and resting. The spent and resting stages, which have been grouped in reproductive studies of penaeids shrimp, were separated for the first time. We observed vesicles accumulated in the cytoplasm of ripe cells. The histological analysis showed oocytes with synchronous development presenting total spawning. The mean length at maturity (CL50) for females was 1.3 cm CL. The reproductive cycle was classified as seasonal for females, with greater ovarian maturity and gonadosomatic index from October to March. The spawning peak occurs during the period of highest rainfall, with a higher percentage of spent females. Taken together, the present findings contribute to the current knowledge on the ovarian morphology, maturation process of penaeids, supporting future studies on reproductive biology which may be useful for sustainable management of commercial penaeid fisheries and reproductive performance of *Xiphopenaeus kroyeri* in captivity.

Keywords: histology, management, maturation, morphology, ovarian maturity.

Listas de figuras

	Página
Introdução:	
Figura 1. Exemplar de <i>Xiphopenaeus kroyeri</i> (Heller 1862) capturado em Lucena, litoral norte da Paraíba, Brasil.	21
Capítulo I. Ovarian morphology and oocyte development in the seabob shrimp <i>Xiphopenaeus kroyeri</i>: a histological and histochemical approach for the study of penaeid reproduction:	
Figure 1. Schematic diagram of the location and morphology of <i>Xiphopenaeus kroyeri</i> ovaries: (a) dorsal view showing ovaries location (green color); (b) lateral view showing ovary location; (c) oviduct located dorsoventrally between the fifth and sixth lateral lobes in the cephalothoracic region; anterior lobes (1), lateral lobes (2), posterior lobes (3) and oviducts (4)	30
Figure 2. Photomicrographs of the <i>Xiphopenaeus kroyeri</i> ovary: (a) longitudinal section of the ovaries showing ovigerous lamellae (OL) and proliferation zone (PZ); (b) details of the ovaries showing connective fibers (Cf) and lining epithelium (Ep); (c) blood vessels containing hemolymph (h) inside, lined by simple squamous epithelium (SS); (d) the lining epithelium (Ep) of the ovaries; (e) thickened layer detail of the Ep composed by collagenous connective fibers (CCf). Staining: MAT (ab); TGO (c-e)	32
Figure 3. Photomicrographs of the oviducts of female <i>Xiphopenaeus kroyeri</i> : a) longitudinal section of the oviduct showing secretory epithelium (SEp) and Lumen of the oviduct (Lum); b) longitudinal section of the oviduct showing stratified columnar epithelium (STC) and muscular epithelium (MEp); c) details of the oviduct showing stratified columnar epithelium (STC) showing acidophilic substance (as) in the Lumen;	

d) details of the oviduct showing secretory epithelium (SEp) and muscular epithelium (MEp). Staining: H/E-P (a, c); GOT (b, d)..... 33

Figure 4. Photomicrographs of the oocyte development of female *Xiphopenaeus kroyeri*: a) oogonia (OO) concentrated in the proliferation zone (PZ); b) oogonia (OO) in detail; c) chromatin nucleolar oocyte (CN); d) chromatin perinucleolar oocyte (CPN); e) primary vitellogenic oocyte (VTG₁) showing cuboidal follicular cells (fc); f) secondary vitellogenic oocyte (VTG₂) showing squamous follicular cells (fc); g) mature oocyte (MO) showing vesicles (V) in detail and squamous follicular cells (fc); h) atretic oocyte (AO) in different degrees of atresia; i) atretic oocyte (AO) showing yolk droplets (yd); Captions: nucleus (n); Staining: H/E-P (a, b, f, g); H (c); GOT (d, e, h, i) 35

Figure 5. Photomicrographs of the oocytes of *Xiphopenaeus kroyeri*: a-b) previtellogenic oocyte showing cell membrane (cmb) and absence of protein droplets (pd); c) primary vitellogenic oocyte (VTG₁) with a small proportion of protein droplets (pd); d) mature oocyte (MO) showing protein droplets (pd) and absence of protein droplets (*); e) previtellogenic oocyte showing absence of collagen; f) primary vitellogenic oocyte (VTG₁) showing yolk droplets (yd) concentrated near the nucleus; g) secondary vitellogenic oocyte (VTG₂) showing larger yolk droplets (yd) concentrated throughout the cytoplasm and discrete deposition of cytoplasmic collagen vesicles (*); h) mature oocyte (MO) in final phase showing collagen deposition (*) larger and concentrated in the periphery of the cytoplasm; i) oogonia (OO) showing absence of neutral polysaccharides; j) perinucleolar oocyte with absence of neutral polysaccharides; k) VTG₁ oocyte showing presence of neutral polysaccharides (NP) throughout the cytoplasm; l) VTG₂ oocyte showing presence of neutral polysaccharides (NP) more concentrated near the nucleus and in the central part of the cytoplasm; m) mature oocyte (MO) showing droplets of neutral polysaccharides (NP) throughout the

cytoplasm, including vesicles at the periphery of mature oocytes. Captions: nucleus (n); cell membrane (cmb); follicular cells (fc); oogonia (OO). Staining: XP (a-d); GOT (e-h); PAS (i-m);

38

Figure 6. Photomicrographs of the follicular complex showing follicular cell morphology in developing oocytes of *Xiphopenaeus kroyeri*: a) cuboidal follicular cells (fc) become clustered in batches or dispersed near previtellogenic oocytes (PVTG); b) cuboidal follicular cells surround chromatin perinucleolar (CPN) oocyte clusters (oocyte II); c) single-layer cuboidal follicular cells surround primary vitellogenic oocytes (VTG₁); d) single-layer squamous follicular cells surround the secondary vitellogenic oocytes (VTG₂); e) external layer to the mature oocyte (MO); f) cuboidal follicular (fc) cells surrounding the atretic oocytes (AO); g-j) follicular cells being differentiated in the cytoplasm showing total proteins highlighted in orange staining. Captions: nucleus (n); vesicles (V) chromatin nucleolar oocyte (CN); chromatin perinucleolar oocyte (CPN); Staining: H/E-P (a-f); XP (g-h);

40

Capítulo II. Métodos utilizados na identificação dos estágios de maturação ovariana macroscópico do *Xiphopenaeus kroyeri*: implicações na determinação da época de desova:

Figure 1. Escala maturacional macroscópica do *Xiphopenaeus kroyeri*: a) escala maturacional macroscópica obtida a partir da visualização dos ovários através do exoesqueleto (Método I) mostrando as cores de ovário mais frequentes de acordo com o catálogo Pantone (I: imaturo, II: em maturação, III: maturo e IV: desovado); b) escala maturacional macroscópica obtida a partir da extração, visualização e observação da morfologia dos ovários frescos (Método II) mostrando as cores dos ovários mais frequentes de acordo com o catálogo Pantone (I: imaturo, II: em maturação inicial, III:

em maturação avançada, IV: maturo, V: desovado, VI: repouso). Legenda: cor translúcida (T)..... 60

Figure 2. Cortes histológicos dos ovários de *Xiphopenaeus kroyeri* mostrando a escala maturacional através do método I representados pelas figuras: I (estágio imaturo), II (em maturação), IV (estágio maturo) e V (Estágio desovado); escala maturacional através do método II representadas pelas figuras: I (imaturo), II (em maturação inicial), III (em maturação avançada), IV (maturo), V (desovado), VI (repouso)..... 62

Figure 3. Período reprodutivo do camarão *Xiphopenaeus kroyeri*: a) período reprodutivo estimado a partir da visualização dos ovários através do exoesqueleto (método I) (I: imaturo, II: em maturação, III: maturo e IV: desovado); b) período reprodutivo estimado a partir da extração, visualização e observação da morfologia dos ovários frescos (método II) (I: imaturo, II: em maturação inicial, III: em maturação avançada, IV: maturo, V: desovado, VI: repouso). 65

Capítulo III: Ovarian maturation stages, size at maturity, spawning type and reproductive cycle of Seabob shrimp *Xiphopenaeus kroyeri* (Decapoda, Penaeidea):

Figure 1. Study area on the north coast of Paraíba State, northeastern Brazil 76

Figure 2. Distribution of absolute frequency per size class (CL – cm) for *X. kroyeri* females (F) and males (M) caught between December 2016 and November 2017 in Lucena, Paraíba state, northeastern Brazil..... 79

Figure 3. Ovarian maturation stages through macroscopic analysis of the shrimp *X. kroyeri* captured in Lucena, Paraíba, northeastern, Brazil. A) stage of ovarian maturation; B) color of the fresh ovary. I: immature (translucent color; T); II: early developing (584 PC); III: advanced developing (384 PC); IV: ripe (575 PC); V: spent (379 PC); VI: resting (translucent color; T). 81

- Figure 4.** Photomicrographs of ovarian maturation in *X. kroyeri*: A-B) immature stage, showing previtellogenic oocytes (PVTG); C-D) early maturing stage, with primary vitellogenic oocytes (VTG₁); E-F) advanced maturing stage, with secondary vitellogenic oocytes (VTG₂); G-H) ripe stage, showing mature oocytes (MO) with vesicles (V) in the cytoplasm; I-J) spent stage, showing atretic oocytes (AO) and postovulatory follicle (POF); K-L) resting stage, with previtellogenic oocytes and flaccid tissue connective (TC). OO: oogonia; NC: nucleolar chromatin; PN: perinucleolar chromatin; ol: ovigerous lots; n: nucleus; FC: follicular cells. Scale bars: figures in left side 200 µm, right side 50 µm, and highlight figures 20 µm (H and J)..... 83
- Figure 5.** Frequency distribution of the oocyte diameter in each phase, in the six ovarian maturation stages of *X. kroyeri* caught in Lucena-PB, northeastern Brazil, between December/2016 to November/2017. I) immature; II) early maturing; III) advanced maturing; IV) ripe; V) spent; VI) resting. Black arrows indicate the most developed oocyte group, while asterisks represent reserve oocytes..... 85
- Figure 6.** Length (cephalothorax, CL) at maturity of *X. kroyeri* females caught between December 2016 and November 2017 in Lucena, Paraíba, northeastern Brazil..... 86
- Figure 7.** Physicochemical variables (salinity and temperature), mean rainfall (last 10 years) and number of mature *X. kroyeri* females caught between December 2016 and November 2017 in Lucena, Paraíba, northeastern Brazil..... 87
- Figure 8.** Relative frequency of ovarian development stages of *X. kroyeri* females caught between December 2016 and November 2017 in Lucena, Paraíba, northeastern Brazil. II: early maturing; III: advanced maturing; IV: ripe; V: spent; VI: resting. GSI: monthly mean and standard deviation of gonadosomatic index (%)..... 88

Listas de tabelas

Página

Capítulo I. Ovarian morphology and oocyte development in the seabob shrimp *Xiphopenaeus kroyeri*: a histological and histochemical approach for the study of penaeid reproduction:

Table 1. Diameter (mean \pm SD, μm) for each oocyte phase of *Xiphopenaeus kroyeri* females in Lucena, Paraíba, northeastern Brazil. 36

Capítulo II. Métodos utilizados na identificação dos estágios de maturação ovariana macroscópico do *Xiphopenaeus kroyeri*: implicações na determinação da época de desova:

Tabela 1. Índice de concordância (%), número de acertos, índice de erros, e número de erros entre os métodos I (visualização dos ovários através do exoesqueleto) e II (extração, visualização e observação da morfologia dos ovários frescos) de avaliação macroscópica quando comparados com a análise histológica dos estágios de maturação ovariano do camarão *Xiphopenaeus kroyeri* 63

Capítulo III: Ovarian maturation stages, size at maturity, spawning type and reproductive cycle of Seabob shrimp *Xiphopenaeus kroyeri* (Decapoda, Penaeidea):

Table 1. Mean (\pm SD) total length (TL, cm), cephalothorax length (CL, cm), total weight (TW, g), ovary weight (OW) and gonadosomatic index (GSI) in six ovarian maturation stages of *X. kroyeri* females in Lucena, Paraíba, northeastern Brazil. 82

Table 2. Frequency and diameter (mean \pm SD) for each oocyte phase observed in each stage (I - VI) of gonadal maturity of *X. kroyeri*. Oogonia (OO), previtellogenic oocytes (PVTG), primary vitellogenic oocytes (VTG₁), secondary vitellogenic oocytes (VTG₂), mature oocytes (MO) and Atretic oocytes (AO). I) Immature; II) Early developing; III) Advanced developing; IV) Ripe; V) Spent; VI) Resting. (-): not present. 84

Lista bilingue de abreviaturas, siglas e símbolos

AO	Atretic oocytes	Ovócito atrésico
as	Acidophilic substance	Substância acidófila
CCf	Collagenous connective fibers	Fibras conjuntivas de colágeno
Cf	Connective fibers	Fibras conjuntivas
CL	Cephalothorax length	Comprimento do cefalotórax
CL50	Mean length at first maturity	Comprimento médio de primeira maturação
cmb	Cell membrane	Membrana celular
CN	Chromatin nucleolar oocyte	Ovócito cromatina nucleolar
CPN	Chromatin perinucleolar oocyte	Ovócito cromatina perinucleolar
Ep	Lining epithelium	Epitélio de revestimento
fc	Follicular cells	Células foliculares
GOT	Gomori's Trichrome	Tricrômico de Gomori
GSI	Gonadosomatic index	Índice Gonadossomático
h	Hemolymph	Hemolinfa
H/ E-P	Hematoxylin and Eosin-Phloxin	Hematoxilina e Eosina-Floxina
Lum	Lumen	Lúmen
MAT	Mallory's Trichrome	Tricrômico de Mallory
Mep	Muscular epithelium	Epitélio muscular
MO	Mature oocytes	Ovócitos maduros
n	Nucleus	Núcleo
NC	Nucleolar chromatin	Cromatina Nucleolar
NP	Neutral polysaccharides	Polissacarídeos neutros
OD	Oocyte diameter	Diâmetro do ovócito
ol	Ovigerous lots	Lotes ovíferos
OL	Ovigerous lamellae	Lamelas ovíferas
OO	Oogonia	Oogônias
OW	Ovary Weight	Peso do ovário
PAS	Periodic acid Schiff	Ácido periódico/ reativo de Schiff
pd	Protein droplets	Gotículas de proteína
PN	Perinucleolar chromatin	Cromatina perinucleolar
POF	Post ovulatory follicle	Folículo pós-ovulatório
PVTG	Pre-vitellogenic oocytes	Ovócitos pré-vitelogênicos

PZ	Proliferation zone	Zona de proliferação
SD	Standard deviation	Desvio padrão
SEp	Secretory epithelium	Epitélio secretor
SS	Squamous epithelium	Epitélio pavimentoso
STC	Stratified columnar epithelium	Epitélio colunar estratificado
TC	Tissue connective	Tecido conjuntivo
TL	Total length	Comprimento total
TW	Total weight	Peso total
V	Vesicles	Vesículas
VTG ₁	Primary vitellogenic oocytes	Ovócitos vitelogênicos primários
VTG ₂	Secondary vitellogenic oocytes	Ovócitos vitelogênicos secundários
XP	Xylidine Ponceau	Ponceau de Xilidina
yd	Yolk droplets	Gotículas de vitelo

Sumário

	página
Resumo	xi
Abstract	xiii
Lista de figuras	xiv
Lista de tabelas	xv
Lista bilingue de abreviaturas, siglas e símbolos	xvi
Sumário	xvii
1. Introdução	20
<i>1.1 Contextualização da pesquisa</i>	20
2. Objetivos	23
<i>2.1 Objetivo geral</i>	23
<i>2.2 Objetivos específicos</i>	23
3. Capítulos da tese	25
3.1 Capítulo I: Ovarian morphology and oocyte development in the seabob shrimp <i>Xiphopenaeus kroyeri</i> : a histological and histochemical approach for the study of penaeid reproduction	25
3.2. Capítulo II: Métodos utilizados na identificação dos estágios de maturação ovariana macroscópico do <i>Xiphopenaeus kroyeri</i> : implicações na determinação da época de desova	55
3.3. Capítulo III: Ovarian maturation stages, size at maturity, spawning type and reproductive cycle of seabob shrimp <i>Xiphopenaeus kroyeri</i> (Decapoda, Penaeidea)	73
4. Considerações finais	101
5. Referências bibliográficas	102

1. Introdução

1.1 Contextualização da pesquisa

Os recursos pesqueiros marinhos representam grande importância social e econômica em todo o mundo, sobretudo no litoral brasileiro. Segundo a Organização das Nações Unidas para Agricultura e Alimentação (FAO, 2014), a exploração mundial destes recursos entre a década de 1950 até o final da década de 1980 apresentou um crescimento contínuo, seguido de um período de pequeno declínio no início da década de 1990. Em meados da década de 1990, ocorreu um crescimento na produção mundial de pescado decorrente da expansão da aquicultura.

A aquicultura contribuiu com 87,5 milhões de toneladas no ano de 2020, representando um grande crescimento nas últimas décadas (FAO, 2022). Por outro lado, a produção pesqueira oriunda da pesca no ano de 2020 está estagnada, apresentando 90,3 milhões de toneladas, sendo 87% de capturas em águas marinhas e 13% em águas continentais. Esta estagnação se deve principalmente a sobre-exploração dos recursos naturais, causado pelo aumento das frotas pesqueiras, intensificação da exploração e falta de plano de gestão para conservação e manutenção dos estoques (FAO, 2014).

A Organização das Nações Unidas para a Alimentação e Agricultura (FAO, 2020) estima que a produção de pescados alcançou a cifra de 179 milhões de toneladas em 2018, sendo 82 milhões de toneladas oriundas de produção aquícola. Desse total, 156 milhões de toneladas foram destinadas ao consumo humano. O consumo anual médio per capita em nível mundial de pescado tem aumentado nas últimas décadas, passando de 9,9 kg em 1960 a 20,2 kg em 2020, com estimativa de 21,4 kg para 2030. Isso representa um aumento de 15%, estimulado pelo aumento da renda e urbanização, melhorias nas práticas pós-captura e as mudanças nas tendências alimentares (FAO, 2022). No Brasil, os brasileiros consomem 10,19 kg/per capita/ano em 2020 segundo o Ministério da Agricultura e Pecuária (MAPA, 2021), e dentre os principais recursos pesqueiros consumidos se encontram os camarões.

A produção mundial de camarão alcançou 3,2 milhões de toneladas oriundas da pesca, apresentando a mesma tendência dos anos anteriores, ficando entre os grupos de maior relevância econômica, juntamente com os atuns, lagostas e cefalópodes (FAO, 2022). O último boletim estatístico da pesca e aquicultura do ano de 2011 divulgado pelo Ministério da Pesca e Aquicultura, a captura anual de camarões peneídeos na costa brasileira foi de 39.000 toneladas, das quais 27% das capturas são da espécie

Xiphopenaeus kroyeri (MPA, 2011). Esta espécie é um importante recurso pesqueiro nas águas brasileiras, apresentando grande importância econômica, social e cultural (Gillett, 2008).

O *X. kroyeri*, ou camarão sete-barbas, como é popularmente conhecido (Figura 1), se distribuí ao longo da costa ocidental do Atlântico, desde a Carolina do Norte, EUA; se estendendo ao longo da América do Sul (Venezuela, Guiana, Suriname, Guiana Francesa) até ao Rio Grande do Sul no Brasil (Pérez-Farfante e Kensley, 1997; Costa et al., 2003); bem como no Pacífico Oriental, na Colômbia (Carvalho-Batista et al., 2019). O ciclo de vida desta espécie ocorre exclusivamente no ambiente marinho, não utilizando o estuário como berçário (Williams, 1965; Holthuis, 1980). Habita zonas costeiras e regiões com maiores profundidades, sendo, no entanto, mais abundante próximo à costa em profundidades até 30 metros (D'Incao, 1999; Costa et al., 2003), e que apresentam substratos arenosos ou lamacentos (Costa et al., 2003; Costa et al., 2007; Boos et al., 2016).



Figura 1. Exemplar de *Xiphopenaeus kroyeri* (Heller 1862) capturado em Lucena, litoral norte da Paraíba, Brasil.

Além de sua importância para a pesca, também apresenta potencial para aquicultura visando a sua utilização como isca-viva (Simões et al., 2017). A pesca recreativa tem se expandido ao longo dos anos e é amplamente praticada na costa brasileira (Freire et al., 2016), mas se baseia na utilização de isca-viva oriunda de populações selvagens, o que torna inviável devido às constantes preocupações com a sobrepesca e a pesca predatória em estuários (Barros et al., 2014; Simões et al., 2017;

Henriques et al., 2018). Além disso, no Brasil não é recomendada a utilização de espécies exóticas de camarão como isca-vivas devido as restrições ambientais. Para atender a esta demanda de mercado e visando uma solução mais ecológica, a criação de espécies nativas de camarão pode ser uma opção. Nos últimos anos, a utilização de espécies nativas como isca-viva tem sido proposta para várias espécies de camarões no Brasil, como *Penaeus paulensis* (Preto et al., 2009), *Macrobrachium amazonicum* (Valenti et al., 2011), *Penaeus brasiliensis* (Jensen et al., 2014) e *Penaeus schmitti* (Barros et al., 2014).

Devido a importância de *X. kroyeri* para a pesca e o recente interesse na aquicultura dessa espécie, torna-se fundamental obter informações sobre o seu processo reprodutivo, uma vez que pode auxiliar no estabelecimento de políticas de gestão que minimizem os impactos da pesca, além de fornecer informações relevantes para a criação dessa espécie em cativeiro.

Dentre os principais estudos realizados para compreender a reprodução dos camarões peneídeos se encontra a classificação dos estágios de desenvolvimento ovariano (Quintero e Gracia, 1998; Peixoto et al., 2003; Simpson e Watling, 2006; Lopes et al., 2014; Bolognini et al., 2017; Garcia et al., 2021; Craveiro et al., 2022). A classificação microscópica dos ovários visa descrever as fases de maturação das gonadas a nível celular e é amplamente utilizada para confirmar as escalas de cores determinadas nas análises macroscópicas (Quintero e Gracia, 1998; Lopes et al., 2014; Rios et al., 2022). A combinação de ambas as análises garante uma descrição mais confiável das fases de maturação do que as estimativas baseadas apenas em observações macroscópicas (Peixoto et al., 2003; Craveiro et al., 2022), o que pode ser útil para estabelecer com maior precisão os parâmetros populacionais para a criação de políticas de gestão e conservação de camarões peneídeos (Peixoto et al., 2003; Simpson e Watling, 2006; Garcia et al., 2021), além de auxiliar no desenvolvimento de tecnologias para a reprodução destes organismos em cativeiro (Peixoto et al., 2002, 2004; Flor et al., 2016). Alguns estudos realizaram a associação da análise histológica e macroscópica em camarões peneídeos (Quintero e Gracia, 1998; Ayub e Ahmed, 2002; Peixoto et al., 2003; Silva et al., 2016; Lopes et al., 2017; Bolognini et al., 2017; Peixoto et al., 2018). No entanto, apesar dos inúmeros estudos há uma falta de padronização nas classificações dos estágios de desenvolvimento gonadal (Craveiro et al., 2022), o que pode comprometer a precisão das análises dos parâmetros populacionais, ocasionando

erros nas estimativas de maturidade para esta espécie, bem como ocasionar erros na precisão da classificação dos estágios durante o manejo de reprodutores em cativeiro.

Neste sentido, os capítulos desta tese buscaram descrever a morfologia ovariana e desenvolvimento dos ovócitos do *X. kroyeri* utilizando diferentes enfoques metodológicos. No capítulo I, uma abordagem histológica e histoquímica foi empregada para compreender a dinâmica dos nutrientes incorporados nos ovócitos durante a vitelogênese. No capítulo II foram testados dois métodos de análise macroscópica ovariana, as quais foram validadas e testadas quanto ao índice de concordância no estabelecimento dos estágios de maturação ovariano de acordo com a análise histológica, bem como as possíveis implicações no período de desova decorrente de possíveis erros nas análises. O capítulo III descreve os estágios de maturação ovariana, o tamanho de maturidade, tipo de desova e ciclo reprodutivo do camarão *X. kroyeri* capturado em Lucena, Paraíba, nordeste do Brasil.

2. Objetivos

2.1 Objetivo geral

Caracterizar a reprodução do camarão *Xiphopenaeus kroyeri* capturado no nordeste do Brasil e suprir lacunas existentes acerca da sua reprodução que vise contribuir para a gestão pesqueira e criação desta espécie.

2.2 Objetivos específicos

Capítulo I: Morfologia ovariana e desenvolvimento dos ovócitos do camarão *Xiphopenaeus kroyeri*: uma abordagem histológica e histoquímica para o estudo da reprodução de peneídeos

- ✓ Descrever a morfologia do sistema reprodutivo feminino do *X. kroyeri*;
- ✓ Detalhar a estrutura ovariana e vasos sanguíneos do *X. kroyeri*;
- ✓ Descrever a composição tecidual dos ovidutos das fêmeas do camarão *X. kroyeri*;
- ✓ Caracterizar o desenvolvimento dos ovócitos e os principais nutrientes acumulados durante a vitelogênese;
- ✓ Descrever a formação do complexo folicular e o papel das células foliculares no desenvolvimento dos ovócitos.

Capítulo II: Métodos utilizados na identificação dos estágios de maturação ovariana macroscópico do *Xiphopenaeus kroyeri*: implicações na determinação da época de desova

- ✓ Descrever os métodos de análise macroscópica;
- ✓ Comparar os métodos de análise macroscópica com a análise histológica;
- ✓ Definir o índice de concordância entre os métodos de análise macroscópica em relação à análise histológica;
- ✓ Avaliar os resultados de cada análise macroscópica em comparação com a análise histológica e verificar as principais implicações com a época de desova.

Capítulo III: Estágios de maturação dos ovários, tamanho na maturidade, tipo de desova e ciclo reprodutivo do camarão *Xiphopenaeus kroyeri* (Decapoda, Penaeidea)

- ✓ Caracterizar os estágios de maturação gonadal de fêmeas macroscopicamente e microscopicamente;
- ✓ Validar as escalas macroscópica e histológica do *Xiphopenaeus kroyeri*;
- ✓ Identificar a estrutura da população;
- ✓ Identificar o tipo de desova e época reprodutiva;
- ✓ Avaliar as variáveis ambientais que influenciam no ciclo reprodutivo;
- ✓ Identificar o tamanho de primeira maturidade (L_{50}) das fêmeas.


3. Capítulos da Tese

3.1 Capítulo I: manuscrito publicado na revista científica *Aquaculture* em 30 de setembro de 2022.

<https://doi.org/10.1016/j.aquaculture.2022.738873>


Aquaculture 562 (2023) 738873


Contents lists available at ScienceDirect



Aquaculture

journal homepage: www.elsevier.com/locate/aquaculture





Ovarian morphology and oocyte development in the seabob shrimp *Xiphopenaeus kroyeri*: a histological and histochemical approach for the study of penaeid reproduction

Cecília Craveiro^{a,*}, Hildemário Castro-Neto^a, Larissa B. Costa^b, Emanuell F. Silva^c, Paulo G. V. de Oliveira^a, Lucas Santos^a, Roberta Soares^a, Silvio Peixoto^{a,*}

^a Universidade Federal Rural de Pernambuco, Departamento de Pesca e Aquicultura, Rua Dom Manoel de Medeiros s/n – Dois Irmãos, 52171-900 Recife, PE, Brazil
^b Universidade Federal de Pernambuco, Departamento de Zoologia, Av. Prof. Moraes Rêgo, s/n, Cidade Universitária, 50760-430 Recife, PE, Brazil
^c Instituto Federal de Educação, Ciência e Tecnologia do Paraíba, Campus Cabedelo, Rua Sena Reis de Cária, 1900 - Jardim Cambuí, 58103-772 Cabedelo, PE, Brazil
^d Universidade Federal do Rio Grande, Instituto de Oceanografia, Av. Itália, km 8, 96202900 Rio Grande, RS, Brazil

ARTICLE INFO

Keywords:
Reproductive biology
Oogenesis
Vitellogenesis
Ovarian maturation

ABSTRACT

Histological and histochemical changes during oocyte development were evaluated in order to establish a model for better understanding nutrient dynamics throughout vitellogenesis and overall penaeid reproduction. Samples of *Xiphopenaeus kroyeri* females (n = 587) at different stages of gonadal maturation were subjected to histological and histochemical analysis for the identification of neutral polysaccharides, total proteins, and tissue differentiation. We observed that the ovarian structure was composed of collagen fibers and oviducts were lined by three layers of epithelium separated by muscular tissue. Oogenesis was classified into six distinct phases: chromatin nucleolar oocytes, chromatin perinucleolar oocytes, oocytes in primary vitellogenesis, oocytes in secondary vitellogenesis, mature oocytes, and atretic oocytes. Histochemical observations suggested that during the previtellogenesis phase, proteins and neutral polysaccharides were not present. However, a progressive increase in these substances occurred from vitellogenic oocytes until their final maturation stage. Follicular cells composed the follicular complex forming an external epithelium in vitellogenic oocytes, and are probably involved in protein transfer during maturation process. Collagen and glycoprotein vesicles were identified in the cytoplasm of mature oocytes of *X. kroyeri*. Taken together, the present findings contribute to the current knowledge on the ovarian morphology and maturation process of penaeids, supporting future studies on reproductive biology and breeding performance in captivity.

1. Introduction

Histological descriptions of the female reproductive system are used in order to better understand reproductive patterns and may provide significant information in establishing applicable guidelines for management of wild stocks and breeding programs of penaeid shrimp (Quintero and Gracia, 1998; Garcia-Bento et al., 2020). In addition, they allow for the understanding of the phenomena occurring at the cellular level during ovarian differentiation, making it possible to more accurately monitor cellular changes during vitellogenic development (Braga et al., 2016), and thus enhance knowledge about female physiology. In the ovaries, oogenesis begins with the proliferation phase, with mitotic

multiplication of the oogonia, followed by the previtellogenic and vitellogenic phases (Garcia-Bento et al., 2020), changing volume due to the accumulation of yolk granules in the oocytes, and finally reaching final maturation when the formation of cortical crypts are observed in the cytoplasm periphery (Ayub and Ahmed, 2002; Bolognini et al., 2017; Craveiro et al., 2019; Garcia et al., 2021).

Xiphopenaeus kroyeri (Heller, 1862), popularly known as the seabob shrimp, is one of the most important penaeid species targeted in commercial fishing in Brazil (MPA, 2012), and in addition is frequently used as live fishing bait (Simões et al., 2017). The seabob shrimp is widely distributed in the Western Atlantic Ocean, occurring from Virginia in the United States, extending along the Caribbean Coast down to the state of

* Corresponding authors.

E-mail addresses: cecliacraveiro@yahoo.com.br (C. Craveiro), silvio.peixoto@gmail.com (S. Peixoto).

<https://doi.org/10.1016/j.aquaculture.2022.738873>

Received 26 May 2022; Received in revised form 21 September 2022; Accepted 25 September 2022

Available online 30 September 2022

0044-8486/© 2022 Elsevier B.V. All rights reserved.

Ovarian morphology and oocyte development in the seabob shrimp *Xiphopenaeus kroyeri*: a histological and histochemical approach for the study of penaeid reproduction

Cecília Craveiro^{1*}, Hildemário Castro-Neto¹, Larissa B. Costa², Emanuell F. Silva³, Paulo G. V. de Oliveira¹, Lucas V. Santos Silva⁴, Roberta Soares¹ and Silvio Peixoto^{1*}

¹Universidade Federal Rural de Pernambuco, Departamento de Pesca e Aquicultura. Rua Dom Manoel de Medeiros s/n – Dois Irmãos, 52171-900, Recife-PE, Brazil.

²Universidade Federal de Pernambuco, Departamento de Zoologia. Av. Prof. Moraes Rego, s/n, Cidade Universitária, 50760-420, Recife-PE, Brazil.

³Instituto Federal de Educação, Ciência e Tecnologia da Paraíba, Campus Cabedelo.

Rua Santa Rita de Cássia, 1900 - Jardim Camboinha, 58103-772, Cabedelo-PB, Brazil.

⁴Universidade Federal do Rio Grande, Instituto de Oceanografia. Av. Itália, km 8, 96203900, Rio Grande-RS, Brazil.

* Corresponding authors: ceciliacraveiro@yahoo.com.br; silvio.peixoto@gmail.com

Abstract

Histological and histochemical changes during oocyte development were evaluated in order to establish a model for better understanding nutrient dynamics throughout vitellogenesis and overall penaeid reproduction. Samples of *Xiphopenaeus kroyeri* females (n = 587) at different stages of gonadal maturation were subjected to histological and histochemical analysis for the identification of neutral polysaccharides, total proteins, and tissue differentiation. We observed that the ovarian structure was composed of collagen fibers and oviducts were lined by three layers of epithelium separated by muscular tissue. Oogenesis was classified into six distinct phases: chromatin nucleolar oocytes, chromatin perinucleolar oocytes, oocytes in primary vitellogenesis, oocytes in secondary vitellogenesis, mature oocytes, and atretic oocytes. Histochemical observations suggested that during the previtellogenesis phase, proteins and neutral polysaccharides were not present. However, a progressive increase in these substances occurred from vitellogenic oocytes until their final maturation stage. Follicular cells composed the follicular complex forming an external epithelium in vitellogenic oocytes, and are probably involved in protein transfer during maturation process. Collagen and glycoprotein vesicles were identified in the cytoplasm of mature

oocytes of *X. kroyeri*. Taken together, the present findings contribute to the current knowledge on the ovarian morphology and maturation process of penaeids, supporting future studies on reproductive biology and breeding performance in captivity.

Keywords: reproductive biology, oogenesis, vitellogenesis, ovarian maturation.

1. Introduction

Histological descriptions of the female reproductive system are used in order to better understand reproductive patterns and may provide significant information in establishing applicable guidelines for management of wild stocks and breeding programs of penaeid shrimp (Quintero and Gracia, 1998; Garcia Bento et al., 2020). In addition, they allow for the understanding of the phenomena occurring at the cellular level during ovarian differentiation, making it possible to more accurately monitor cellular changes during vitellogenic development (Braga et al., 2016), and thus enhance knowledge about female physiology. In the ovaries, oogenesis begins with the proliferation phase, with mitotic multiplication of the oogonia, followed by the previtellogenic and vitellogenic phases (Garcia Bento et al., 2020), changing volume due to the accumulation of yolk granules in the oocytes, and finally reaching final maturation when the formation of cortical crypts are observed in the cytoplasm periphery (Ayub and Ahmed, 2002; Bolognini et al., 2017; Craveiro et al., 2019; Garcia et al., 2021).

Xiphopenaeus kroyeri (Heller, 1862), popularly known as the seabob shrimp, is one of the most important penaeid species targeted in commercial fishing in Brazil (MPA, 2012), and in addition is frequently used as live fishing bait (Simões et al., 2017). The seabob shrimp is widely distributed in the Western Atlantic Ocean, occurring from Virginia in the United States, extending along the Caribbean Coast down to the state of Rio Grande do Sul in Brazil (Costa et al., 2003). This species is a potential candidate in projects targeting the use of shrimp bait in aquaculture (Simões et al., 2017), as is being developed with other native shrimp in Brazil (Preto et al., 2009; Valenti et al., 2011; Jensen et al., 2014; Barros et al., 2014; Valenti et al., 2021). Recreational fishing has been increasing in importance and it is widely practiced on the Brazilian coast (Freire et al., 2016). In order to support such activity, a large demand for live shrimp bait has been mostly supplied by capturing juveniles from natural stocks, which raises concerns about overfishing and predatory fishing in estuaries (Barros et al.,

2014; Simões et al., 2017; Henriques et al., 2018). Furthermore, since the use of non-native species as live bait (e.g. *Litopenaeus vannamei*) is a point of debate and is subject to restrictions in Brazil, the most feasible solution is the development of bait aquaculture using native species, such as the seabob shrimp (Preto et al., 2009; Barros et al., 2014; Simões et al., 2017; Henriques et al., 2018).

There is little information available about the ovarian maturation of *X. kroyeri*, and studies describing the gonadal development have reported conflicting results about its final ovarian maturation. Lopes et al. (2017) observed the presence of cortical rods at the final stage of maturation, as is commonly described in most studies with penaeids (e.g. Ayub and Ahmed, 2002; Farhana and Ohtomi, 2016; Bolognini et al., 2017; Peixoto et al., 2018; Craveiro et al., 2019). By contrast, a recent study by Craveiro et al. (2022) did not find the presence of cortical rods in mature oocytes. Instead, they noted that vesicles accumulated in the cell's cytoplasm. Additionally, the above authors emphasized the importance of further investigations into the final maturation phase of the species using histochemical techniques, in addition to providing detailed information on the oogenesis process and nutrient accumulation patterns during vitellogenesis.

One of the most common approaches to obtaining more details about oogenesis is through histochemical analysis of the oocytes, in which it is possible to better understand the cellular processes associated with vitellogenesis and the chemical nature of nutrients incorporated during oocyte maturation of crustaceans (Zara et al., 2011; Braga et al., 2016). Despite this, the pattern of nutrient accumulation that occurs in the oogenesis of penaeid shrimp is poorly addressed in the literature, such as in the studies by King (1948), Yano (1988), and Tan-Fermin and Pudadera (1989). Studies associating histological and histochemical analysis of oogenesis are particularly important for shrimp species of economic interest (Zara et al., 2011), as they allow for more refined analyses seeking to determine the composition of organic molecules that are mobilized during vitellogenesis (Nicolau et al., 2012; Zara et al., 2011; Braga et al., 2016), and may contribute to the improvement of techniques employed in breeding programs and reproduction performance in captivity (Chung et al., 2011; Corral-Rosales et al., 2018).

The present study aimed to describe the ovarian morphology and the oogenesis dynamics of *X. kroyeri* using histological and histochemical approaches. Specific information is provided about ovarian lining, accessory structures that assist in the

maturation process, and histochemical characteristics of compounds found in the oocytes, in addition to their storage patterns along the vitellogenesis of *X. kroyeri*.

2. Material and methods

2.1. Study area and sampling

The study was conducted in the municipality of Lucena (6°53'50" S and 34°51'01" W) on the northern coast of the state of Paraíba, Northeast, Brazil. Samples of *X. kroyeri* were collected monthly from December 2016 to November 2017, and from March 2018 to November 2019 using a beach seine net (side length of body mesh: 2 cm; side length of cod-end mesh: 1.5 cm; mouth opening area: 120 × 6 m) deployed from a small non-motorized craft. The specimens were immediately stored on ice and transported to the laboratory, where sexing was performed based on the presence of thelycum.

2.2. Histological and histochemical analysis

Histological and histochemical analyses were performed on 587 females, randomly selected at different stages of gonadal maturation (123 immature, 98 early developing, 115 advanced developing, 43 ripe, 52 spent and 156 resting stages according to Craveiro et al. 2022). The ovaries were dissected from the dorsal body cavity and samples from the median portion were fixed in Davidson's saline solution for 24 hours and preserved in 70% ethanol for 24 hours. They were then routinely processed by dehydration using a graded ascending set of ethanol (80%, 90%, 95%, and absolute), clarified in xylene, and finally impregnated and embedded in paraffin at 57° C. Slides were prepared in 5 µm thick sections using a rotary microtome (Leica RM2145, Leica Microsystems, Germany).

The sections were stained with Hematoxylin and Eosin-Phloxin (H/E-P) for the identification of acidic and basic substances; Periodic Acid Schiff for the detection of neutral polysaccharides (PAS); Mallory's Trichrome (MAT), and Gomori's Trichrome (GOT) for the detection of collagen and tissue differentiation (adapted from Junqueira and Junqueira, 1983) and Xylidine Ponceau (XP) for the detection of total proteins (Vidal, 1977). Slides were observed under a light microscope (Leica DM500) equipped with a digital camera (Leica ICC50HD). The photomicrographs of the slides were digitized with Leica software LAS EZ 3.4 (Leica Microsystems) with objectives from 4× to 100× magnification.

2.3 Data Analysis

The oocytes were classified microscopically into different development phases and 300 oocytes per category were measured using Leica LAS EZ 3.4 (Leica Microsystems). Oocyte diameter was measured only in those cells sectioned in the equatorial plane and with a visible nucleus. The oocyte diameters at each phase were compared using analysis of variance (ANOVA), meeting the necessary assumptions of homogeneity and homoscedasticity. Tukey's test was applied in order to identify oocytes that were significantly different from each other ($p < 0.05$).

3. Results

3.1 Morphology of the female reproductive system

The female reproductive system of *X. kroyeri* is composed of paired ovaries of the tubular structure. Each portion of the ovary has one anterior lobe in the cephalothoracic region, six lateral lobes with the last lobe being shorter than the others, and one long posterior lobe extending into the abdominal region (Figure 1). Additionally, each portion of the ovary has an oviduct located dorsoventrally between the fifth and sixth lateral lobes in the cephalothoracic region, which connect to the gonopores located at the base of the third pair of pereopods (Figure 1b, c).

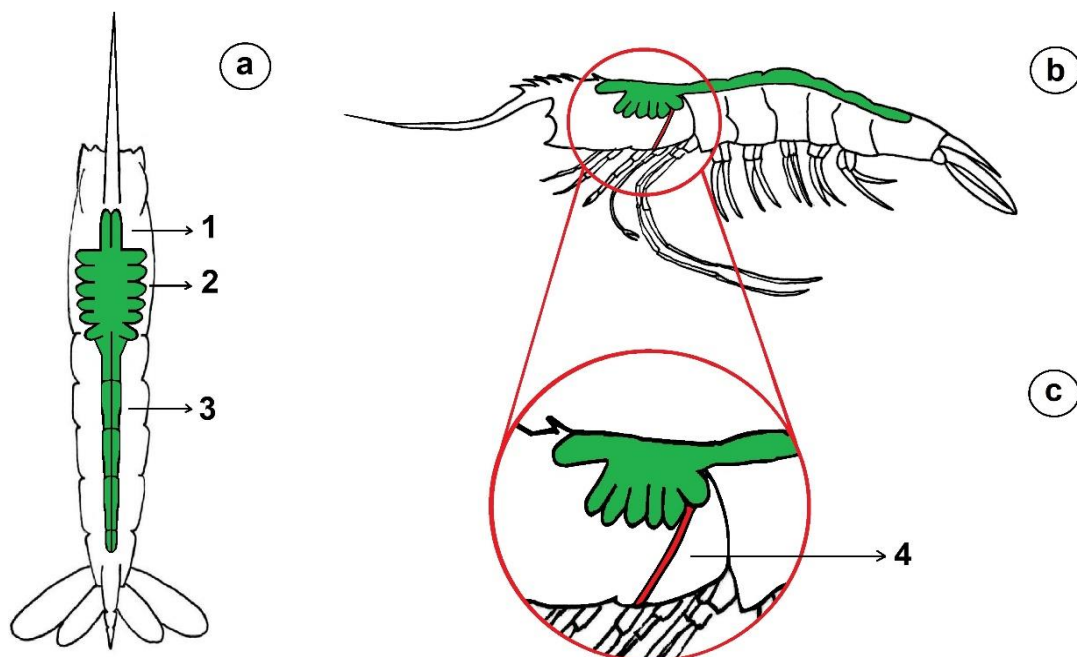


Fig. 1. Schematic diagram of the location and morphology of *Xiphopenaeus kroyeri* ovaries: (a) dorsal view showing ovaries location (green color); (b) lateral view showing ovary location; (c) oviduct located dorsoventrally between the fifth and sixth lateral lobes in the cephalothoracic region; anterior lobes (1), lateral lobes (2), posterior lobes (3) and oviducts (4).

The ovaries change in color, consistency, and turgidity during their maturation development, becoming darker in color at each stage of maturation, which can be observed through the exoskeleton filling the entire dorsal cavity. Turgidity begins gradually and homogeneously in the anterior, lateral, and posterior lobes until the complete filling of the dorsal cavity occurs by the ovary (Figure 1). Likewise, the change in coloration also occurs homogeneously throughout the ovarian lobes with the progression of maturation.

3.2 Ovarian structure and blood vessels

The ovaries are internally composed of ovigerous lamellae (OL) consisting of loose connective tissue with collagen fibers evidenced in blue by MAT, which support oogonia in the proliferation zone and the oocytes (Fig. 2a, b). The lining of the ovaries is collagenous connective fibers evidenced in green by GOT (Fig. 2 c, d, e). After the lining layer a thickened layer composed by collagenous connective fibers can be observed (Fig. 2b, e).

Blood vessels containing granular material (i.e. hemolymph) reacting positively to eosin and GOT were seen inside the ovarian lobules. The vessels are lined by simple squamous epithelium consisting of collagen fibers, identified by a positive reaction to GOT (Fig. 2 c).

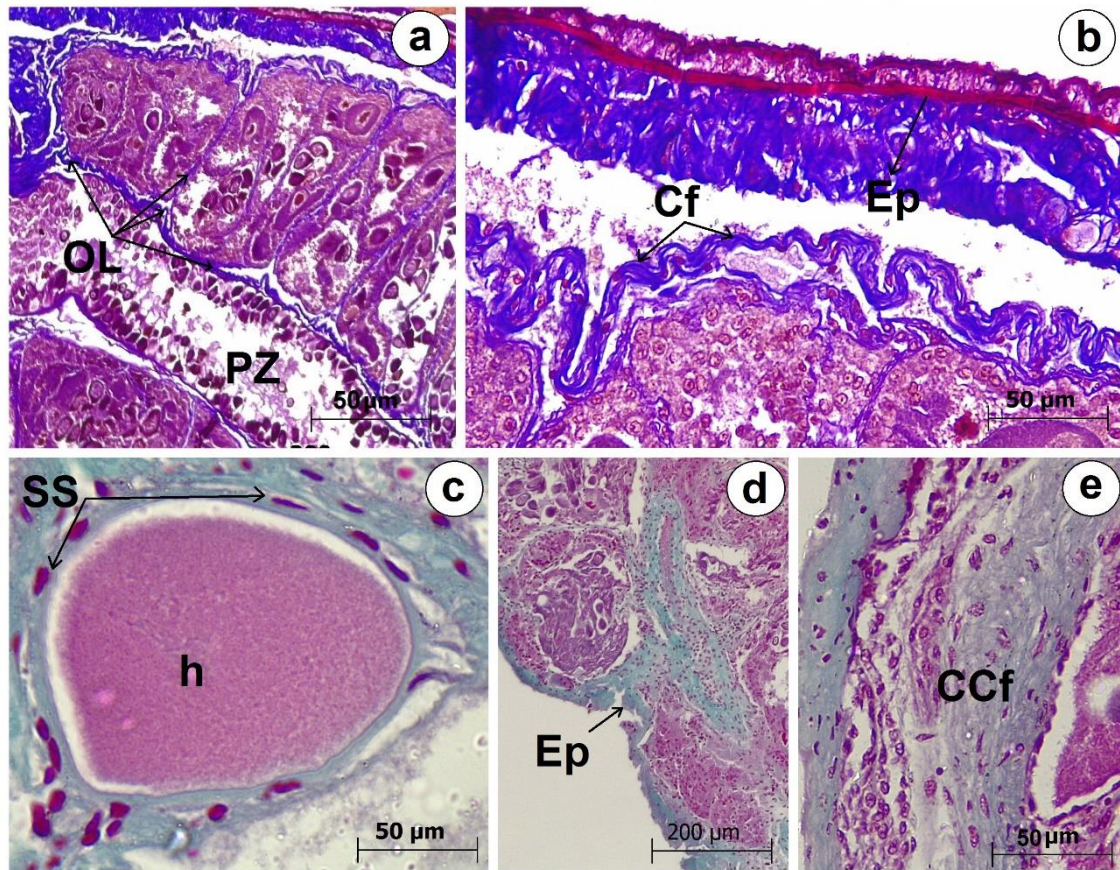


Fig. 2. Photomicrographs of the *Xiphopenaeus kroyeri* ovary: (a) longitudinal section of the ovaries showing ovigerous lamellae (OL) and proliferation zone (PZ); (b) details of the ovaries showing connective fibers (Cf) and lining epithelium (Ep); (c) blood vessels containing hemolymph (h) inside, lined by simple squamous epithelium (SS); (d) the lining epithelium (Ep) of the ovaries; (e) thickened layer detail of the Ep composed by collagenous connective fibers (CCf). Staining: MAT (a-b); TGO (c-e).

3.3 Oviducts

The oviducts are lined internally by three layers: the internal layer is composed of columnar secretory epithelium (SEp), the middle and external layers are composed of stratified columnar epithelium (STC) evidenced by GOT in purple, separated by muscular epithelium (MEp) evidenced in magenta color (Fig. 3).

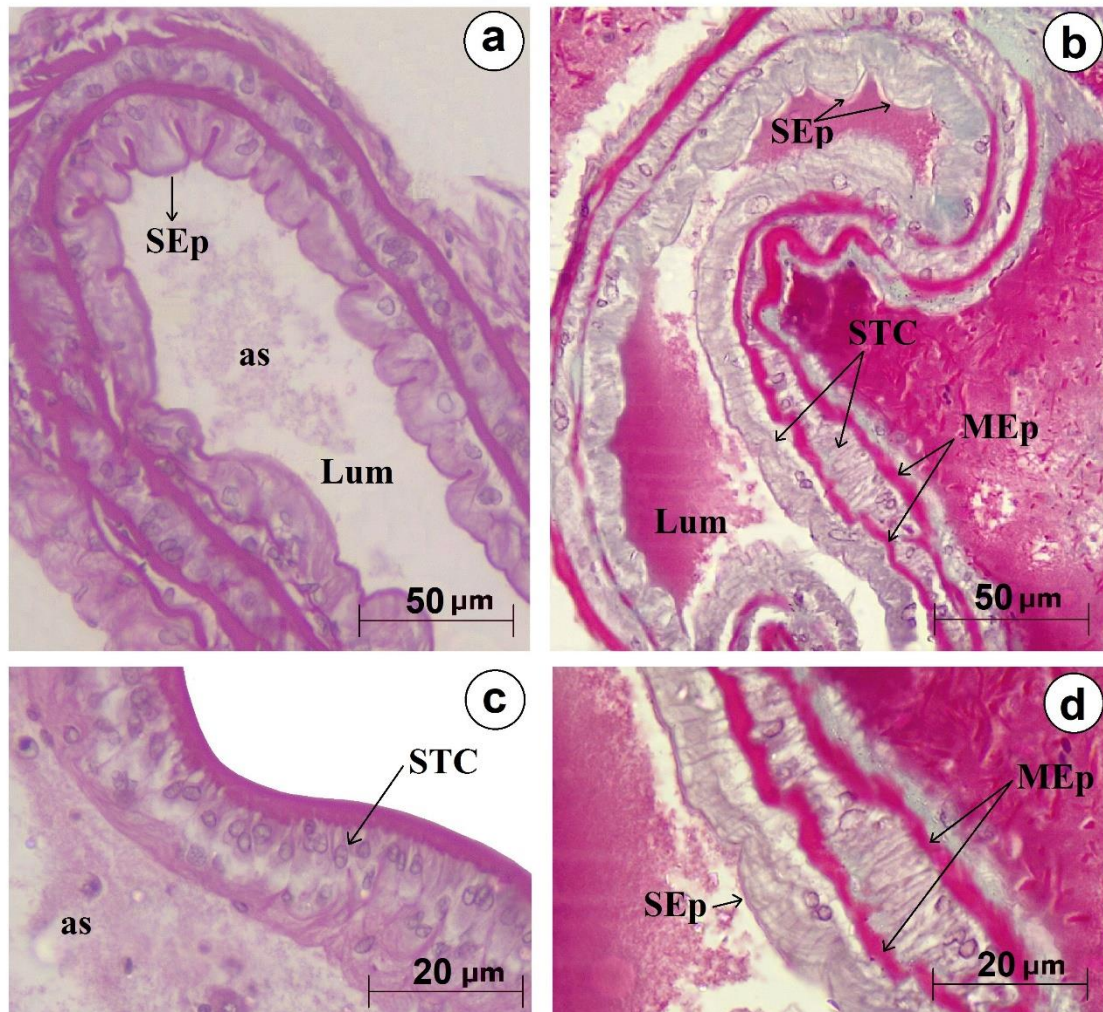


Fig. 3. Photomicrographs of the oviducts of female *Xiphopenaeus kroyeri*: a) longitudinal section of the oviduct showing secretory epithelium (SEp) and Lumen of the oviduct (Lum); b) longitudinal section of the oviduct showing stratified columnar epithelium (STC) and muscular epithelium (MEp); c) details of the oviduct showing stratified columnar epithelium (STC) showing acidophilic substance (as) in the Lumen; d) details of the oviduct showing secretory epithelium (SEp) and muscular epithelium (MEp). Staining: H/E-P (a, c); GOT (b, d).

3.4 Oocyte development and follicular complex formation

The maturation phases of oocytes from *X. kroyeri* were determined based on the morphological changes and yolk production observed in different germ cells. Moreover, oocyte size differed significantly among phases. The phases were classified as follows: Oogonia: oogonia are grouped in the proliferation zone (PZ) and are frequently observed in the cell division process. These small cells present a thin layer of basophilic

cytoplasm surrounding the nucleus, having an average diameter of $9.35 \pm 2.08 \mu\text{m}$ (Table 1, Fig. 4 a, b).

Oocyte I: chromatin nucleolar (CN) is the first phase of previtellogenic oocytes. The nucleus is large and centrally located, surrounded by a layer of cytoplasm and containing a single large nucleolus. This oocyte has an average diameter of $21.17 \pm 5.43 \mu\text{m}$ (Table 1, Fig. 4 c).

Oocyte II: chromatin perinucleolar oocyte (CPN) is the second phase of the previtellogenic oocyte, showing an increase in size and multiple nucleoli organized at the periphery of the nucleus. CPNs have an average diameter of $41.36 \pm 11.38 \mu\text{m}$ (Table 1, Fig. 4 d).

Oocyte III: primary vitellogenic oocytes (VTG_1) are moderately eosinophilic and presented yolk droplets distributed in the cytoplasm around the nucleus area. VTG_1 have an average diameter of $97.72 \pm 7.28 \mu\text{m}$ (Table 1, Fig. 4 e).

Oocyte IV: secondary vitellogenic oocytes (VTG_2) have yolk droplets throughout the entire cytoplasm. VTG_2 have an average diameter of $135.16 \pm 16.12 \mu\text{m}$ (Table 1, Fig. 4 f).

Oocyte V: mature oocytes (MO) are characterized by the appearance of vesicles distributed throughout the cytoplasm area, with the largest size at its periphery. These vesicles are filled with a granular material, which reacts positively to Phloxin. Mature oocytes have an average diameter of $187.66 \pm 23.57 \mu\text{m}$ (Table 1, Fig. 4 g).

Oocyte VI: atretic oocytes (AO) are mature oocytes in ovary resorption (Fig. 4 (h, i)). Different degrees of atresia may be observed but they were not measured (Table 1, Fig. 4 h).

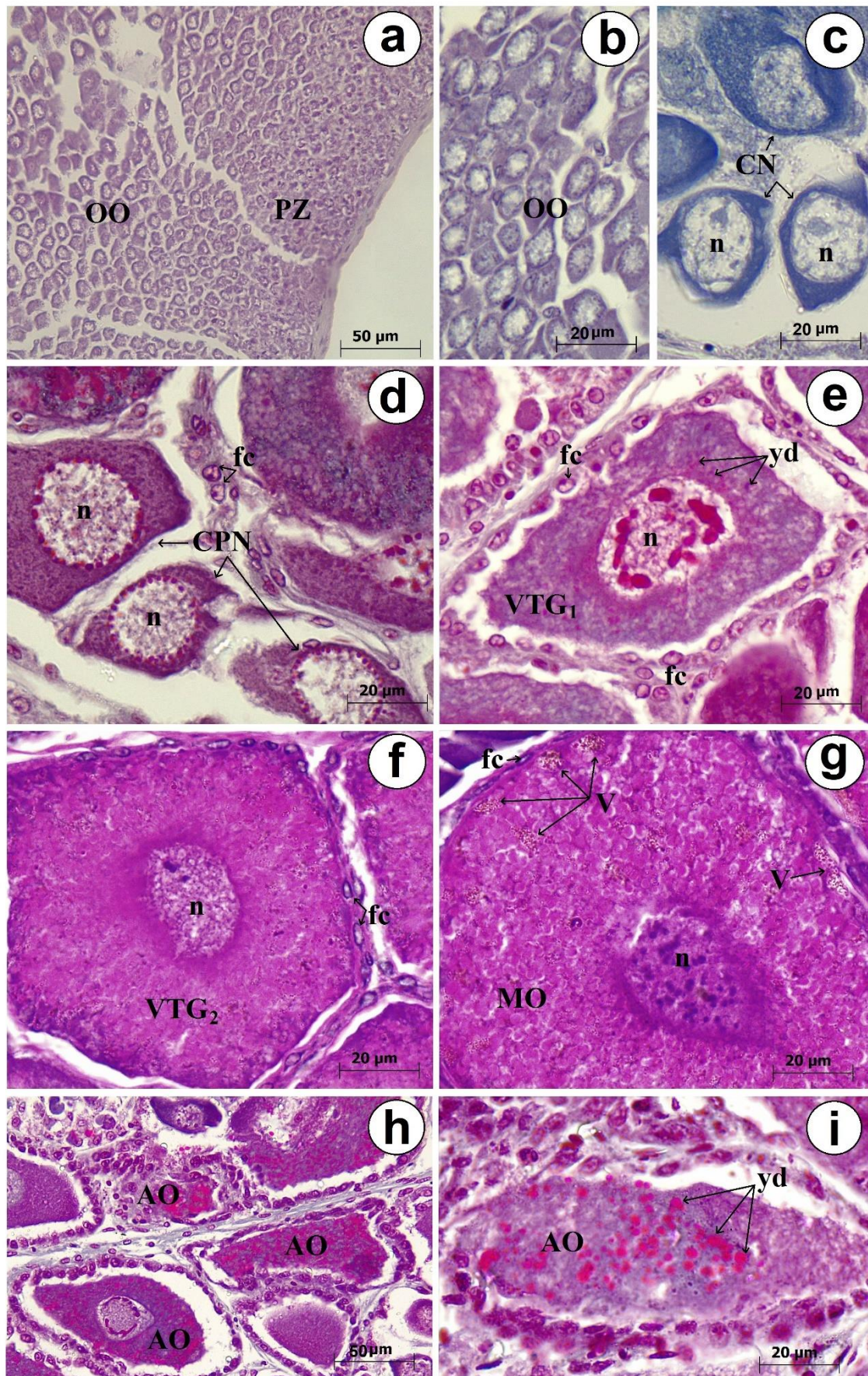


Fig. 4. Photomicrographs of the oocyte development of female *Xiphopenaeus kroyeri*: a) oogonia (OO) concentrated in the proliferation zone (PZ); b) oogonia (OO) in detail; c) chromatin nucleolar oocyte (CN); d) chromatin perinucleolar oocyte (CPN); e) primary vitellogenic oocyte (VTG₁) showing cuboidal follicular cells (fc); f) secondary vitellogenic oocyte (VTG₂) showing squamous follicular cells (fc); g) mature oocyte (MO) showing vesicles (V) in detail and squamous follicular cells (fc); h) atretic oocyte (AO) in different degrees of atresia; i) atretic oocyte (AO) showing yolk droplets (yd); Captions: nucleus (n); Staining: H/E-P (a, b, f, g); H (c); GOT (d, e, h, i).

Table 1. Diameter (mean \pm SD) for each oocyte phase of *Xiphopenaus kroyeri* females in Lucena, Paraíba, northeastern Brazil.

Oocyte phase	Diameter (μm) *
Oogonia (OO)	9.35 \pm 2.08 ^a
Chromatin nucleolar oocytes (CN)	21.17 \pm 5.43 ^b
Chromatin perinucleolar oocytes (CPN)	41.36 \pm 11.36 ^c
Primary vitellogenic oocytes (VTG ₁)	97.72 \pm 7.28 ^d
Secondary vitellogenic oocytes (VTG ₂)	135.16 \pm 16.12 ^e
Mature oocytes (MO)	187.66 \pm 23.57 ^f
Atretic oocytes (AO)	**

Values in the same column with different superscript letters are significantly different ($p < 0.05$).

* Sample number of 300 oocytes for each phase.

** not measured.

Histochemical analysis of the different oocyte types allowed for the observation of the accumulation of proteins and collagen (Figure 5). In oogonia, oocytes I and II revealed a red pigmentation when subjected to the XP stain. However, they did not show protein droplets (Fig. 5 a, b). By contrast, in oocytes III a small proportion of protein droplets was observed (Fig. 5 (c)), which became more evident and numerous in oocytes V (Fig. 5 d). Cell membrane (cmb) in fuchsia color was evident from the beginning of oocyte I until the end of maturation when it becomes thicker (Fig. 5 d), showing that this membrane has protein in its composition. The vesicles present in mature oocytes (V) were not identified by the XP technique. Atretic oocytes showed the

presence of protein, but not collagen droplets. The deposition of a small amount of collagen (Fig. 5 e-h) began to be observed in VTG₂ oocytes (IV - Fig. 5 g). Collagen droplets become larger and more numerous in mature oocytes, forming larger vesicles that move to the peripheral region of the cytoplasm (Fig. 5 h), although they can also be observed throughout the cytoplasm.

Germ cells reacted positively to PAS from VTG₁ (Fig. 5 k-m), which means that neutral polysaccharides accumulate as the vitellogenesis process begins. In addition to being composed of collagen, vesicles presented in the cytoplasm of mature oocytes also have neutral polysaccharides (Fig. 5 l, m).

Follicular cells compose the follicular complex and change their shape and location in the ovaries during maturation (Fig. 6). At first, cubic follicular cells were dispersed within oogonia or clustered near oocytes I (Fig. 6 a), while further, they formed clusters surrounding oocytes II (Fig. 6 b). Although oocyte maturation began with the emergence of oocytes I and II, follicular complex formation began only in oocytes at the primary vitellogenesis (III) stage, which was characterized by a single layer of cubic follicular cells (Fig. 6 c). As maturation progressed, the follicular cells became squamous (Fig. 6 d), and finally formed an external layer to the ripe oocytes (Fig. 6 e). When atretic oocytes emerged after spawning, the follicular cells became cubic again, while part of them degenerated into the ovary (Fig. 6 f).

Histochemically, the follicular cells reacted to XP indicating the presence of proteins in their cytoplasm regardless of the ovarian development or oocyte stage. Small proportions of orange-stained protein droplets could be noted in the cytoplasm of follicle cells at the beginning of maturation, increasing in proportion in VTG₁, VTG₂, and MO oocytes (Fig. 6 h-j).

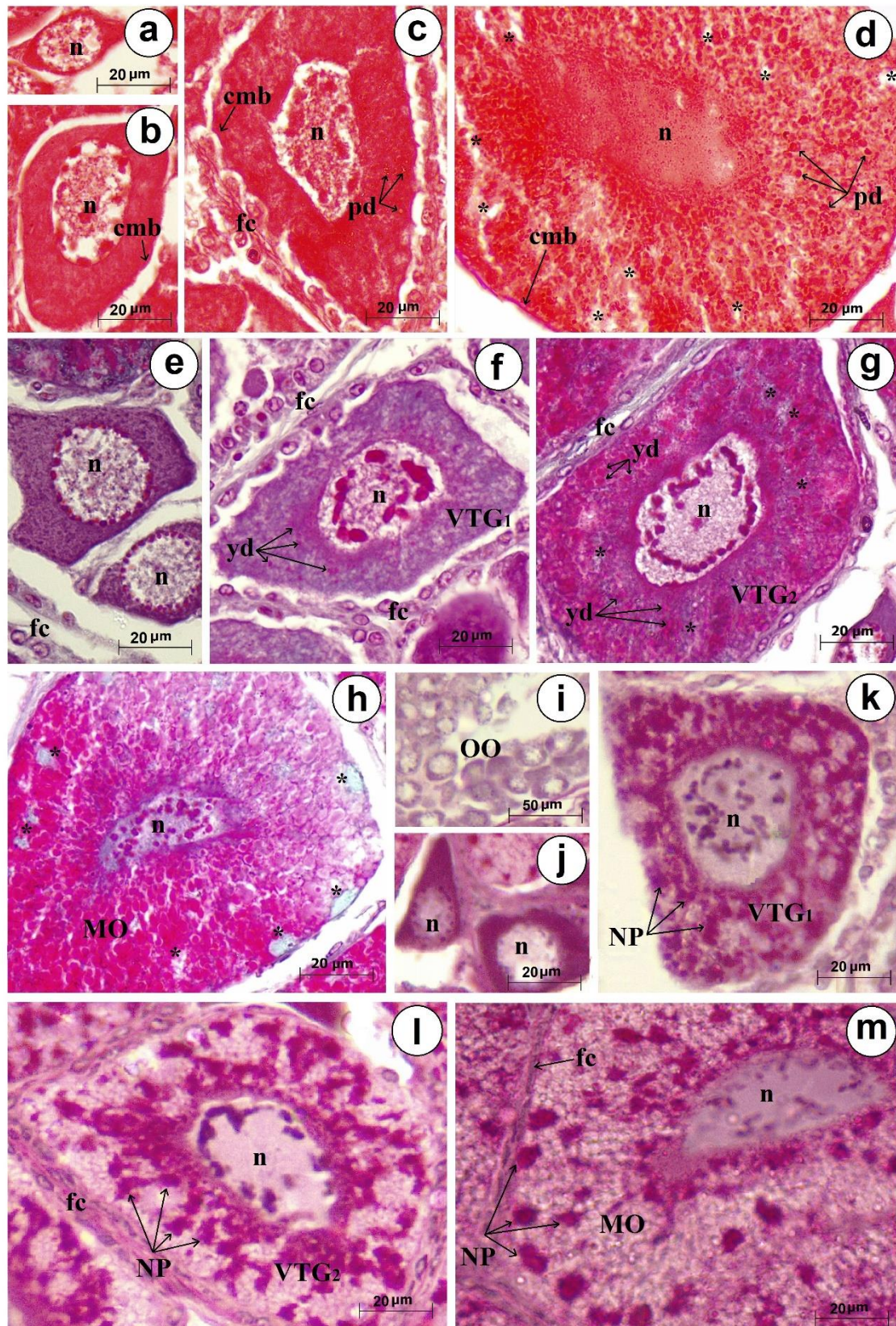


Fig. 5. Photomicrographs of the oocytes of *Xiphopenaeus kroyeri*: a-b) previtellogenic oocyte showing cell membrane (cmb) and absence of protein droplets (pd); c) primary

vitellogenic oocyte (VTG₁) with a small proportion of protein droplets (pd); d) mature oocyte (MO) showing protein droplets (pd) and absence of protein droplets (*); e) previtellogenic oocyte showing absence of collagen; f) primary vitellogenic oocyte (VTG₁) showing yolk droplets (yd) concentrated near the nucleus; g) secondary vitellogenic oocyte (VTG₂) showing larger yolk droplets (yd) concentrated throughout the cytoplasm and discrete deposition of cytoplasmic collagen vesicles (*); h) mature oocyte (MO) in final phase showing collagen deposition (*) larger and concentrated in the periphery of the cytoplasm; i) oogonia (OO) showing absence of neutral polysaccharides; j) perinucleolar oocyte with absence of neutral polysaccharides; k) VTG₁ oocyte showing presence of neutral polysaccharides (NP) throughout the cytoplasm; l) VTG₂ oocyte showing presence of neutral polysaccharides (NP) more concentrated near the nucleus and in the central part of the cytoplasm; m) mature oocyte (MO) showing droplets of neutral polysaccharides (NP) throughout the cytoplasm, including vesicles at the periphery of mature oocytes. Captions: nucleus (n); cell membrane (cmb); follicular cells (fc); oogonia (OO). Staining: XP (a-d); GOT (e-h); PAS (i-m);

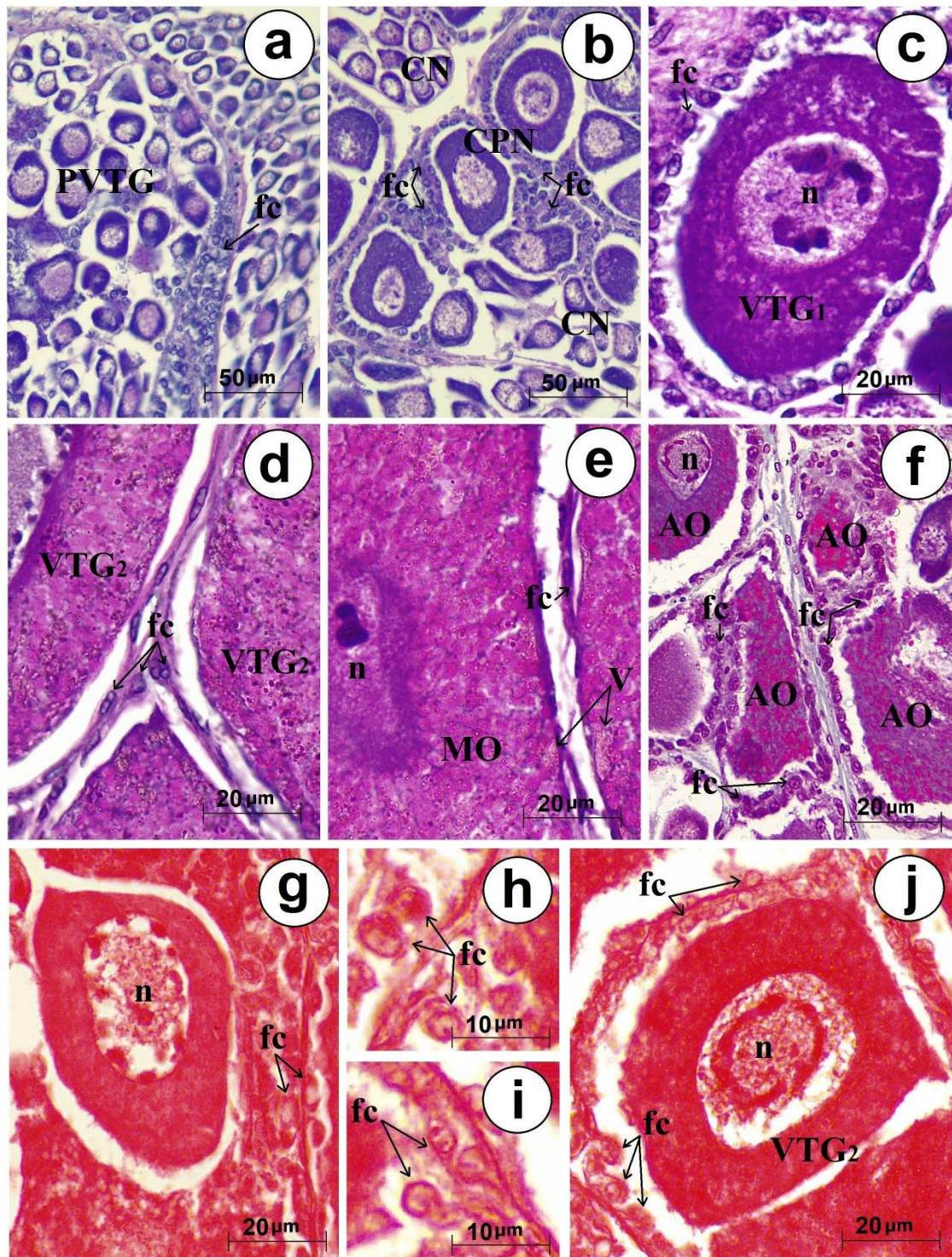


Fig. 6. Photomicrographs of the follicular complex showing follicular cell morphology in developing oocytes of *Xiphopenaeus kroyeri*: a) cuboidal follicular cells (fc) become clustered in batches or dispersed near previtellogenic oocytes (PVTG); b) cuboidal follicular cells surround chromatin perinucleolar (CPN) oocyte clusters (oocyte II); c) single-layer cuboidal follicular cells surround primary vitellogenic oocytes (VTG₁); d) single-layer squamous follicular cells surround the secondary vitellogenic oocytes

(VTG₂); e) external layer to the mature oocyte (MO); f) cuboidal follicular (fc) cells surrounding the atretic oocytes (AO); g-j) follicular cells being differentiated in the cytoplasm showing total proteins highlighted in orange staining. Captions: nucleus (n); vesicles (V) chromatin nucleolar oocyte (CN); chromatin perinucleolar oocyte (CPN); Staining: H/E-P (a-f); XP (g-h);

4. Discussion

General anatomy of the ovary of *X. kroyeri* is in accordance with previous descriptions for penaeids (King, 1948; Worsmann et al., 1976, Dall et al., 1990; Harrison, 1990; Browdy, 1992; Garcia et al., 2021). Coloration, degree of turgidity, size, and texture of the ovaries change with the progression of maturation (O'Donovan et al., 1984; Quintero and Gracia, 1998; Peixoto et al., 2003; Craveiro et al., 2019; Garcia et al., 2021), which was also observed in the present study. These morphological changes occurring in the ovaries have been demonstrated to be closely related to the pattern of nutrient accumulation and oocyte development (Zara et al. 2011; Braga et al. 2016). Although morphological descriptions of ovaries are routinely used in hatcheries to select ready-to-spawn females (Alfaro-Montoya, 2013; Ceballos-Vázquez et al., 2003), the knowledge about corresponding histological characteristics is crucial in order to improve accuracy in staging ovarian maturation and to establish guidelines for penaeid breeding programs (Quintero and Gracia, 1998; Braga et al., 2016; Garcia Bento et al., 2020).

We noted that the ovarian structure of *X. kroyeri* is composed of collagen fibers. Previous studies on penaeids have only reported the presence of fibrous material, such as *Penaeus setiferus* (King, 1948) and *Penaeus paulensis* (Neiva et al., 1971; Worsmann et al., 1976), although no histochemical analysis was performed in these studies. Collagen fibers give strength and elasticity to their constituent organs; in this regard, we may assume that collagen fibers give the ovary the ability to change to the degree of turgidity throughout the oocyte maturation process, until spawning occurs, and then the reproductive cycle is resumed.

The description of the oviducts lined with three layers is first reported for penaeids in the present study. The internal layer is composed of secretory epithelium, the middle and external layers are composed of stratified columnar epithelium, separated by muscular epithelium. Krol et al. (1992) and Bell and Lightner (1988) described the existence of only one layer of simple columnar epithelium for penaeid

species. The presence of columnar epithelium is indicative of the occurrence of secretory activity, as observed by King (1948) for *P. setiferus*. Nevertheless, these previous studies did not report muscular epithelium in the oviducts. We hypothesized that the muscular epithelium layers assist with the transport of oocytes until they reach the gonopores. Moreover, the presence of a homogeneous acidophilic pink-stained substance can be observed in the lumen of the oviduct, confirming secretory activity in the oviduct, which may also facilitate in the oocyte expulsion process.

Studies on the ovarian maturation of wild penaeid broodstocks have been used as a starting point for the development of captive breeding (Tan-Fermin and Pudadera, 1989; Tan-Fermin, 1991; Medina et al. 1996; Palacios et al., 1999; Peixoto et al., 2003, 2005), since controlled reproduction is considered an important step in order to determine the technological package for candidate species for aquaculture (Alfaro-Montoya et al. 2018). Furthermore, improving reproductive capacity of domesticated broodstocks is a constant challenge for commercial hatcheries worldwide. Reproductive performance has been related to quality of feed given to broodstock (Bray & Lawrence, 1990; Wouters et al, 2001a), but there is little information available on nutrient incorporation patterns throughout the vitellogenesis process.

Identification of oocyte developmental stages based on histological and histochemical patterns in penaeids was previously reported only by King (1948) for *P. setiferus*, Yano (1988) for *Penaeus japonicus*, and Tan-Fermin and Pudadera (1989) for *Penaeus monodon*. Oogonia and oocyte I showed cytoplasm strongly reactive to hematoxylin, lacking in neutral polysaccharides and collagen. Polysaccharides began to accumulate only in oocyte II. In the ovaries of *Exhippolysmata oplophoroides*, polysaccharides were detected in previtellogenic oocytes, which were considered the first reserves to be accumulated in this species (Braga et al. 2016), as indicated in our study. *X. kroyeri* oocytes presented neutral polysaccharides (glycoproteins) as reported for several penaeid species (Lynn and Clark, 1987; Tan-Fermin and Pudadera, 1989; Clark et al., 1990; Yamano et al., 2004; Kruevaisayawan et al., 2007). Zara et al. (2011) argued that these glycoproteins are also the first reserves stored during previtellogenesis and increased during the ovarian maturation of *Callinectes danae*.

Total protein deposition in oocytes I and II of *X. kroyeri* showed homogeneous positive staining throughout the cytoplasm, not differentiating between these stages. Braga et al. (2016) observed the presence of proteins in oocytes of *E. oplophoroides* and suggested that they were important for embryo development and juvenile survival. In

the present study, protein granules were also observed in small proportions dispersed in the cytoplasm of oocytes III, evidenced in orange color by XP. Furthermore, they increased in number and pigmentation in oocytes IV and filled the entire cytoplasm of oocytes V in small red droplets. Some authors suggest that an increase in protein content in mature ovaries was related to rapid oocyte growth during the last stages of vitellogenesis for *P. japonicus* (Yano and Chinzei, 1987), *Macrobrachium rosenbergii* (Lee and Chang, 1997), *Penaeus aztecus* and *P. setiferus* (Castille and Lawrence, 1989).

Accumulation of nutrients during ovarian maturation was associated with a progressive increase in the gonadosomatic index due mainly to lipids and proteins (Mourente and Rodrigues, 1991; Spaargaren and Haefner, 1994; Cavalli et al., 2001; Wouters et al., 2001). In the present study, as *X. kroyeri* maturation progressed, a proportional increase in cytoplasm area occurred, which is indicated by the mean diameter of each oocyte stage. Oocyte sizing is a useful tool in comparing reproductive performance between wild and captive females, as several studies have reported that captive ones showed smaller oocytes which has been related to lower hatching performance (Peixoto et al. 2005), in addition to inferior larval quality (Palacios et al., 1999; Ceballos-Vázquez et al., 2003; Arcos et al., 2005, 2011). According to Quackenbush (1989), the quantity of yolk protein in penaeid eggs can affect larval survival. Corral-Rosales et al. (2018) noted that early vitellogenesis occurred when biochemical reserves stored in different tissues were mobilized to the ovary. Accordingly, a rapid increase can be noted in the size of oocytes after stage III in the present study. Possibly yolk incorporation was the factor responsible for such abrupt change in oocyte diameter (Quackenbush, 1989; Yano et al., 1996; Craveiro et al., 2019), since yolk granules started accumulating near the nucleus of oocytes III and then dispersed throughout the cytoplasm in larger droplets until final maturation.

Formation of cortical crypts in mature oocytes is an important feature of the final stage of maturation and occurs immediately before spawning in penaeids (Tan-Fermin and Pudadera, 1989). These structures assist in the attachment of sperm, forming the hatching bundle, and may have antimicrobial activity (Clark Jr. et al., 1980; Yano, 1988; Kruevaisayawan et al., 2007). However, cortical crypts were not observed in the present study for *X. kroyeri*. Instead, we observed vesicles consisting of collagen and glycoprotein accumulating in the cytoplasm and increasing in size as the oocyte maturation progresses. These vesicles were not rod-shaped or spherical-shape and are not organized occupying the entire periphery of the cytoplasm, which differentiates

them from the cortical crypts of mature oocytes reported for several penaeids (Ayub and Ahmed, 2002; Peixoto et al., 2003; Silva et al., 2016; Craveiro et al., 2019; Garcia et al., 2021). Although the absence of cortical crypts is rare, it has also been reported for some penaeid species, such as *Metapenaeopsis dalei* (Sakaji et al., 2000), *Metapenaeopsis monoceros* (Abraham e Manisseri, 2012), *Penaeus indicus* (Henry et al., 2019), *Metapenaeopsis sibogae* and *Metapenaeopsis provocatoria owstoni* (Rahman e Ohtomi, 2017; 2020). Lynn and Clark (1987) observed for *P. aztecus* that cortical crypts consisted mainly of proteins and carbohydrates. In the present study, the vesicles showed presence of neutral polysaccharides (i.e. glycoproteins), which have also been reported in the cortical crypts of mature penaeid oocytes by several authors (Lynn and Clark, 1987; Tan-Fermin and Pudadera, 1989; Clark et al., 1990; Yamano et al., 2003; Kruevaisayawan et al., 2007). Craveiro et al. (2022) argued that the chemical composition of the vesicles in *X. kroyeri* would probably be different from the cortical crypts of other penaeids, based on their characteristics using standard histological analysis with Hematoxylin and Eosin, which was proved histochemically in the present study. Nevertheless, despite the morphological and histochemical differences between these structures, we suggest that the vesicles found in *X. kroyeri* may have the same or similar function as the cortical crypts in mature oocytes of other penaeids. However, studies on how fertilization occurs in *X. kroyeri* and other species that have vesicles in the final maturation process are needed in order to confirm this hypothesis.

Atretic oocytes were observed in resorption, as reported by several authors in penaeid ovaries after spawning (Tan-Fermin and Pudadera, 1989; Silva et al., 2016; Bolognini et al., 2017; Lopes et al., 2017; Craveiro et al., 2019; Garcia et al., 2021). Histochemical staining of atretic oocytes showed the presence of yolk droplets distributed throughout the cell (Figure 4i), but no collagen granules were observed, even in oocytes at the beginning of atresia. This fact may indicate that collagen is possibly the first substance to be reabsorbed by the ovary when the oocyte reaches final maturation. Occurrence of atretic oocytes has been used to determine the spawning season of wild penaeid stocks, being an important parameter in estimating the recruitment dynamics for the purpose of management of fisheries (Silva et al., 2016; Bolognini et al., 2017; Lopes et al., 2017). Furthermore, atresia has also been linked to reproductive performance of penaeid broodstocks, as an indication of ovarian regression when occurred prior to final maturation stages and poor fecundity when it is abundant after spawning (Palacios et al. 1999; Peixoto et al. 2005).

Follicular cells compose the follicular complex, forming an external layer around the vitellogenic oocytes, and they are also organized in clusters near or surrounding the germ cells during maturation of *X. kroyeri*. Other studies have also reported this pattern of follicular cells for penaeid species, such as *P. setiferus* (King, 1948) and *P. paulensis* (Worsmann et al., 1976). Throughout ovarian maturation, follicular cells show morphological changes, varying from cubic to fused appearance from the beginning to the end of ovarian maturation, respectively, corroborating the observations of Tan-Fermin and Pudadera (1989) for *P. monodon*. In *P. japonicus* it was suggested that follicular cells may synthesize vitellogenin, which is secreted into the hemolymph and then absorbed by the oocytes (Yano and Chinzei, 1987). By contrast, Braga et al. (2016) argued for *E. oplophoroides* that changes in the shape of follicle cells during oocyte maturation would not seem to be related to vitellogenin production *per se*, but rather to the transfer of components from the hemolymph to the oocytes and chorion formation. In the present study, we observed that follicular cells are involved in at least one histochemical process during *X. kroyeri* oogenesis since a differentiation was noted in pigmentation of proteins in their cytoplasm as vitellogenesis progressed. Adiyodi and Subramonian (1983) observed in their studies for decapod crustaceans that cubic follicular cells are responsible for the atresia process. According to them, such cells possess hydrolytic enzymes that may participate in the digestion process of the yolk granules. In the present study, we observed that follicular cells help in the maturation process; however, the relationship of these cells and the atresia process was not clear and needs to be further investigated. According to Chaves and Magalhaes (1993), follicular cells undergo cellular hypertrophy during the atresia process, returning to the cubic shape of the initial stage of vitellogenesis, which in this case corroborates our observations for *X. kroyeri*.

In summary, the histological observations of oocyte development for *X. kroyeri* led us to define, for the first time for penaeids, oogenesis into six distinct stages: nucleolar oocyte, perinucleolar oocyte, oocyte in primary vitellogenesis, oocyte in secondary vitellogenesis, mature oocyte, and atretic oocyte. Our histochemical findings suggest that protein accumulation does not occur during pre-vitellogenesis, but a progressive increase in proteins, neutral polysaccharides, and collagen takes place starting from vitellogenic oocytes until their final maturation. Instead of cortical crypts, which are structures usually found in mature penaeid oocytes, vesicles composed of collagen and glycoproteins were identified in the final maturation. Follicular cells form

an external layer around vitellogenic oocytes and may be involved in transferring proteins into germ cells. The present results are useful not only to improve the knowledge about the nutrients that are incorporated throughout vitellogenesis, but also the overall ovarian maturation process of penaeids.

5. References

Abraham, J., Manisseri, M.K., 2012. Histological and morphological changes associated with ovarian development of speckled shrimp *Metapenaeus monóceros* (Fabricius, 1798). Indian J. Fish. 59(1), 119–124. Available at <http://eprints.cmfri.org.in/id/eprint/8933>

Adiyodi, R.G., Subramonian, T., 1983. Arthropoda-Crustacea. In: Adiyodi KG, Adiyodi R G. (Eds): Reproductive Biology of Invertebrates. Vol I. Oogenesis, Oviposition, and Oosorption, pp. 443–495. Wiley & Sons, New York.

Alfaro-Montoya, J., 2013. Descripción histológica de la oogenesis y espermatogénesis del camarón de cultivo *Litopenaeus vannamei*. Rev. biol. mar. oceanogr. 48(2), 335-344. <https://doi.org/10.4067/S0718-19572013000200012>

Arcos, F.G., Racotta, I.S., Palacios, E., Ibarra, A.M., 2005. Ovary development at the onset of gametogenesis is genetically determined and correlated with reproductive traits at maturity in shrimp *Litopenaeus (Penaeus) vannamei*. Marine Biology. 148, 339-346. <https://doi.org/10.1007/s00227-005-0087-1>

Arcos-Ortega, F.G., Ibarra, A.M., Racotta, I.S., 2011. Vitellogenin in hemolymph predicts gonad maturity in adult female *Litopenaeus (Penaeus) vannamei* shrimp. Aquaculture, 316, 93-98. <https://doi.org/10.1016/j.aquaculture.2011.02.045>

Ayub, Z., Ahmed, M.A., 2002. Description of the ovarian development stages of penaeid shrimp from the coast of Pakistan. Aquac. Res. 33(10), 767-776. <https://doi.org/10.1046/j.1365-2109.2002.00715.x>

Barros, L. C., Barreto, O. J. S., Henriques, M. B., 2014. The economic viability for the production of live baits of white Shrimp (*Litopenaeus schmitti*) in recirculation culture system. Aquac. Int. 22: 1925–1935. <https://doi.org/10.1007/s10499-014-9792-4>

Bell, T.A., Lightner, D.V., 1988. A Handbook of Normal Penaeid Shrimp Histology. Baton Rouge: The World Aquaculture Society. 114 p.

Bolognini, L., Donato, F., Lucchetti, A., Olivotto, I., Truzzi, C., Randazzo, B., Antonucci, M., Illuminati, S., Grati, F., 2017. A multidisciplinary approach to study the reproductive biology of wild prawns. *Sci. Rep.* 7(1), 16781. <https://doi.org/10.1038/s41598-017-16894-1>

Braga, A.A., Nunes, E.T., Lopez-Greco, L.S., Camargo- Mathias, M.I., Fransozo, V., 2016. Histological and histochemical features of the oogenesis in the simultaneous protandric hermaphrodite shrimp *Exhippolysmata oplophoroides* (Decapoda: Caridea). *Micron.* 88, 60-67. <https://doi.org/10.1016/j.micron.2016.06.002>

Bray, W. A., Lawrence, A. L., 1990. Reproduction of eyestalk-ablated *Penaeus stylirostris* fed various levels of total dietary lipid. *Journal of the World Aquaculture Society*, 21, 41–52. <https://doi.org/10.1111/j.1749-7345.1990.tb00952.x>

Browdy, C.L., 1992. A review of the reproductive biology of *Penaeus* species: perspectives on controlled shrimp maturation systems for high-quality nauplii production. In: Wyban, J. (Ed.). *Proceedings of the Special Session on Shrimp Farming*. Florida, USA. pp.22-51.

Campos, B.R., Dumont, L.F.C., D’Incao, F., Branco, J.O., 2009. Ovarian development and length at first maturity of the sea-bob-shrimp *Xiphopenaeus kroyeri* (Heller) based on histological analysis. *Nauplius.* 17, 9-12. Available at https://crustacea.org.br/wp-content/uploads/2014/02/nauplius-v17n1a02.Campos.et_al_.pdf

Castille, F.L., Lawrence, L.A., 1989. Relationship between maturation and biochemical composition of gonads and digestive glands of shrimps *Penaeus aztecus* Ives and *Penaeus setiferus* (L.). *Journal Crustacea Biology.* 9, 202–211. <https://doi.org/10.1163/193724089X00025>

Cavalli, R.O., Tamtin, M., Lavens, P., 2001. Variations in lipid classes and fatty acid content in tissues of wild *Macrobrachium rosenbergii* (de Man) females during maturation. *Aquaculture.* 193, 311–324. [https://doi.org/10.1016/S0044-8486\(00\)00497-X](https://doi.org/10.1016/S0044-8486(00)00497-X)

Ceballos-Vazquez, B. P., Rosas, C., & Racotta, I. S. 2003. Sperm quality in relation to age and weight of white shrimp *Litopenaeus vannamei*. *Aquaculture*, 228 (1–4), 141–151. [https://doi.org/10.1016/S0044-8486\(03\)00322-3](https://doi.org/10.1016/S0044-8486(03)00322-3)

Chaves, P.T.C., Magalhães, C., 1993. O desenvolvimento ovocitário em *Macrobrachium amazonicum* (Heller, 1862) (Crustacea: Decapoda: Palaemonidae), camarão dulcícola da Região Amazônica. *Acta Amazônica*.23 (1), 17-23. <https://doi.org/10.1590/1809-43921993231023>

Chung, M.Y., Liu, C.H., Chen, Y.N., Cheng, W. 2011. Enhancing the reproductive performance of tiger shrimp, *Penaeus monodon*, by incorporating sodium alginate in the broodstock and larval diets. *Aquaculture*. 312, 180–184. <https://doi.org/10.1016/j.aquaculture.2010.11.047>

Clark-Jr, W.H., Lynn, J.W., Persyo, H.O., 1980. Morphology of the cortical reaction in the eggs of *Penaeus aztecus*. *Biol. Bull.* 158(2), 175-186. <https://doi.org/10.2307/1540929>

Clark Jr, W.H., Yudin, A.I., Lynn, J.W., Griffin, F.J., Pillai, M.C., 1990. Jelly layer formation in Penaeoidean shrimp eggs. *Biol. Bull.* 178, 295–299. <https://doi.org/10.2307/1541831>

Corral-Rosales, D.C., Cruz-Suárez, L.E., Ricque-Marie, D., Rodríguez-Jaramillo, C., Palacios, E., 2018. Modulation of reproductive exhaustion using *Ulva clathrata* in Pacific white shrimp *Litopenaeus vannamei* (Boone, 1931) broodstock during commercial maturation. *Aquac Res.* 49, 3711–3722. <https://doi.org/10.1111/are.13839>

Costa, R.C., Fransozo, A., Melo, G.A.S., Morais, F.A., 2003. Chave ilustrada para identificação dos camarões (Dendrobranchiata) do Litoral norte do Estado de São Paulo, Brasil. *Biota Neotrop.* 3(1), 1-12. <https://doi.org/10.1590/S1676-06032003000100011>

Craveiro, C., Peixoto, S., Silva, E., Castro-Neto, H., Eduardo, L., Lira, A., Frédou, F.L., Soares, R., 2019. Reproductive dynamics of the white shrimp *Litopenaeus schmitti* (Burkenroad, 1936) in a beach seine fishery in northeastern Brazil. *Invertebr. Reprod. Dev.* 63(2), 111–121. <https://doi.org/10.1080/07924259.2019.1575923>

Craveiro, C., Castro-Neto, H., Silva, E. F., Soares, A., Lira, A. S., Eduardo, L. N., Frédou, F. L., Soares, R., Peixoto, S., 2022. Ovarian maturation stages, size at maturity, spawning type and reproductive cycle of seabob shrimp *Xiphopenaeus kroyeri* (Decapoda, Penaeidea). Manuscript submitted for publication (copy on file with author).

Crisp, J.A., D'Souza, F.M.L., Tweedley, J.R., Partridge, G.J., Moheimani, N.R., 2017. Quantitative determination of ovarian development in penaeid prawns (Decapoda:

Penaeidae). Journal of Crustacean Biology. 37(1), 81–89.
<https://doi.org/10.1093/jcbiol/ruw001>

Dall, W., Hill, B.J., Rothlisberg, P.C., Staples, D.J., 1990. The biology of the penaeidae. Advances in marine biology. London: Academic Express.

Farhana, Z., Ohtomi, J., 2016. Ovarian maturation, size at sexual maturity, and spawning season of *Parapenaeus fissuroides* crosnier, 1985 (Decapoda: penaeidae). Journal of crustacean biology. 36(6), 815-822. <https://doi.org/10.1163/1937240X-00002483>

Freire, K. M. F., Tubino, R. A., Monteiro-Neto, C., Andrade-Tubino, M. F., Belruss, C. G., Tomás, A. R. G., Tutui, S. L. S., Castro, P. M. G., Maruyama, L. S., Catella, A. C., Crepaldi, D. V., Daniel, C. R. A., Machado, M. L., Mendonça, J. T., Moro, P. S., Motta, F. S., Ramires, M., Silva, M. H. C., Vieira, J. P., 2016. Brazilian recreational fisheries: current status, challenges and future direction. Fish. Manag. Ecol. 23: 276-290. <https://doi.org/10.1111/fme.12171>

Garcia, R.C.P., Craveiro, C.F.F., Bernabé, C.V., Silva, M.A., Aride, P.H.R., Oliveira, A.T., Gonçalves, F.R.S.C., Santander-Neto, J., Lavander, H.D., Faggio, C., 2021. Gonadal Development of Females of the White Shrimp *Penaeus schmitti* (Burkenroad, 1936) Caught in Southeastern Brazil. J. Mar. Sci. Eng. 29, 653. <https://doi.org/10.3390/jmse9060653>

Garcia-Bento, M.A., Nascimento, F.A., Mantelatto, F.L., Zara, F.J., 2020. Ovarian development in swimming crabs: comparative histochemistry and ultrastructure of *Callinectes ornatus* and *Arenaeus cribrarius* (Brachyura, Portunidae). Tissue Cell. 66, 101395. <https://doi.org/10.1016/j.tice.2020.101395>.

Harrison, K.E. 1990. The role of nutrition in maturation, reproduction and embryonic development of decapod crustaceans: A review. Journal of Shellfish Research. 9, 1-28.

Henriques, B. M., Fagundes, L., Petesse, M. L., da Silva, N. J. R., Rezende, K. F. O., Barbieri, E., 2018. Lambari fish *Deuterodon iguape* as an alternative to live bait for estuarine recreational fishing. Fish. Manag. Ecol. 25: 400–407. <https://doi.org/10.1111/fme.12308>

Henry, C.B., Mulanda, C.A., Njiru, J., 2019. Ovarian Development of the Penaeid Shrimp *Penaeus Indicus* (Decapoda): A Case for the Indian Ocean Coastal Waters of Kilifi Creek, Kenya. Fish Aqua J. 10, 262. <https://doi.org/10.4172/2150-3508.1000262>

- Jensen L., Furtado P. S., Fugimura M. M., Garcia L. O., Poersch L. H., Verani J. R., Wasielesky W., 2014. The effect of stocking density on the transport of pink shrimp *Farfantepenaeus brasiliensis* (Crustacea: Decapoda), as live bait for sport fishing in Brazil. *Latin American Journal of Aquatic Research*, 42, 204-212. <https://doi.org/103856/vol42-issue1-fulltext-17>
- King, J.E., 1948. A study on the reproductive organ of the common marine shrimp *Penaeus setiferus* (Linnaeus). *Biol. Bull.* 94(3), 244-262. <https://doi.org/10.2307/1538251>
- Krol, R.M., Hawkins, W.E., Overstreet, R.M., 1992. Reproductive Components. In: Harrison, F. W., Humes, A. G. (eds.) *Microscopic Anatomy of Invertebrates*, v. 10: Decapod Crustacea. New York: Wiley- Liss, p. 295-343.
- Kruevaisayawan, H., Vanichviriyakit, R., Weerachatanukul, W., Magerd, S., Withyachumnarnkul, B., Sobhon, P., 2007. Biochemical characterization and physiological role of cortical rods in black tiger shrimp, *Penaeus monodon*. *Aquaculture*. 270(1-4), 289-298. <https://doi.org/10.1016/j.aquaculture.2007.04.004>
- Lee, F.Y., Chang, C.F., 1997. The concentrations of vitellogenin (vitellin) and protein in hemolymph, ovary, and hepatopancreas in different ovarian stages of the freshwater prawn, *Macrobrachium rosenbergii*. *Comparative Biochemistry and Physiology Part A: Physiology*. 117(4), 433-439. [https://doi.org/10.1016/S0300-9629\(96\)00260-5](https://doi.org/10.1016/S0300-9629(96)00260-5)
- Lopes, D., Frédou, F.L., Silva, E., Calazans, N., Peixoto, S., 2017. Reproductive cycle of seabob shrimp *Xiphopenaeus kroyeri* (Crustacea, Penaeidea) from the northeast coast of Brazil. *Invertebr. Reprod. Dev.* 61, 1-5. <https://doi.org/10.1080/07924259.2017.1311951>
- Lynn, J.W., Clark Jr, W.H., 1987. Physiological and biochemical investigations of the egg jelly release in *Penaeus aztecus*. *The Biological Bulletin*. 173(3), 451-460. <https://doi.org/10.2307/1541692>
- Medina, A., Vila, Y., Mourente, G., Rodrigues, A., 1996. A comparative study of the ovarian development in wild and pond-reared shrimp, *Penaeus kerathurus* (Forsk., 1775). *Aquaculture*. 148, 63-75. [https://doi.org/10.1016/S0044-8486\(96\)01408-1](https://doi.org/10.1016/S0044-8486(96)01408-1)
- Mourente, G., Rodriguez, A., 1991. Variation in the lipid content of wild-caught females of the marine shrimp *Penaeus kerathurus* during sexual maturation. *Mar. Biol.* 110, 21-28. <https://doi.org/10.1007/BF01313088>

Ministério da Pesca e Aquicultura (MPA). 2012. Boletim Estatístico da Pesca e Aquicultura. Ministério da Pesca e Aquicultura, Brasília. p. 129. Available at https://www.icmbio.gov.br/cepsul/images/stories/biblioteca/download/estatistica/est_2011_bol__bra.pdf

Neiva, G.S., Wortmann, T.U., Oliveira, M.T., Valenti, H., 1971. Contribuição ao estudo da maturação da gônada feminina do “camarão rosa” (*Penaeus paulensis* Pérez Farfante, 1967). Bol. Inst. Pesca. S. Paulo. 1 (4), 23-38. Available at <https://www.pesca.agricultura.sp.gov.br/boletim/index.php/bip/article/view/11>

Nicolau, C.F., Nascimento, A.A., Machado-Santos, C., Sales, A., Oshiro, L.M.Y., 2012. Gonads of males and females of the mangrove tree crab *Aratus pisonii* (Grapsidae: Brachyura: Decapoda): a histological and histochemical view. Acta Zoologica. 93:222-230. <https://doi.org/10.1111/j.1463-6395.2011.00516.x>

O'Donovan, P., Abraham, M., Cohen, D., 1984. The ovarian cycle during the intermolt in ovigerous *Macrobrachium rosenbergii*. Aquaculture 36: 347-358. [https://doi.org/10.1016/0044-8486\(84\)90327-2](https://doi.org/10.1016/0044-8486(84)90327-2)

Palacios, E., Rodríguez-Jaramillo, C., Racota, I.S., 1999. Comparison of ovary histology between different-sized wild and pond-reared shrimp *Litopenaeus vannamei* (*Penaeus vannamei*). Invertebrate Reproduction & Development. 35(3), 251-259. <https://doi.org/10.1080/07924259.1999.9652391>

Peixoto, S., Calazans, N., Silva, E.F., Nole, L., Soares, R., Fredou, F.L., 2018. Reproductive cycle and size at first sexual maturity of the white shrimp *Litopenaeus schmitti* (Burkenroad, 1936) in northeastern Brazil. Lat. Am. J. Aquat. Res. 46(1), 1-9. <http://dx.doi.org/10.3856/vol46-issue1-fulltext-1>

Peixoto, S., Cavalli, R.O., D'Incao, F., Milach, Â.M., Wasielesky, W., 2003. Ovarian maturation of wild *Farfantepenaeus paulensis* in relation to histological and visual changes. Aquaculture Research. 34, 1255-1260. <http://dx.doi.org/10.1046/j.1365-2109.2003.00933.x>

Peixoto, S., Cavalli, R.O., D'Incao, F., Wasielesky, W., Milach, Â.M., 2002. A comparative study of the ovarian histology of eyestalk ablated and unablated *Farfantepenaeus paulensis* after spawning. Bol. Inst. de Pesca 28 (1), 71-76. Available at <https://pesca.agricultura.sp.gov.br/boletim/index.php/bip/article/view/Peixoto>

Peixoto, S., Coman, G., Arnold, S., Crocos, P., Preston, N., 2005. Histological examination of final oocyte maturation and atresia in wild and domesticated *Penaeus monodon* (Fabricius) broodstock. *Aquaculture Research*. 36, 666-673. <https://doi.org/10.1111/j.1365-2109.2005.01271.x>

Preto, A.L., Pisseti, T.L., Wasielesky, W.J., Poersch, L.H., Cavalli, R.O., 2009. Production of live bait-shrimp (*Farfantepenaeus paulensis*) in cages at varying stoking densities. *Bol. Inst. Pesca*. 35, 39-45.

Quackenbush, L.S., 1989. Vitellogenesis in the shrimp, *Penaeus vannamei*: in vitro studies of the isolated hepatopancreas and ovary. *Comparative Biochemistry and Physiology*. 94, 253-261. [https://doi.org/10.1016/0305-0491\(89\)90342-8](https://doi.org/10.1016/0305-0491(89)90342-8)

Quintero, M.E.S., Gracia, A., 1998. Stages of gonadal development in the spotted pink shrimp *Penaeus brasiliensis*. *J. Crust. Biol.* 18 (4), 680-685. <https://doi.org/10.1163/193724098X00548>

Rahman, M. M., Ohtomi, J., 2017. Reproductive biology of the deep-water velvet shrimp *Metapenaeopsis sibogae* (De Man, 1907) (Decapoda: Penaeidae). *Journal of Crustacean Biology*. 37, 743–752. <https://doi.org/10.1093/jcbiol/rux084>

Rahman, M.M., Ohtomi, J., 2020. Ovarian maturation, size at sexual maturity, and spawning season of *Metapenaeopsis provocatoria owstoni* Shinomiya & Sakai, 2000 (Decapoda: Penaeidae). *Crustacean Research*. 49, 109–120. https://doi.org/10.18353/crustacea.49.0_109

Sakaji, H., Tsuchiya, K., Segawa, S., 2000. Oocyte development of *Metapenaeopsis dalei* (Penaeidae, Decapoda, Crustacea). *Invertebrate Reproduction & Development*. 38, 7–12. <https://doi.org/10.1080/07924259.2000.9652431>

Silva, E.F., Calazans, N., Nolé, L., Castelo-Branco, T., Soares, R., Guerra, M.M.P., Frédou, F.L., Peixoto, S., 2016. Reproductive dynamics of the southern pink shrimp *Farfantepenaeus subtilis* in northeastern Brazil. *Aquat Biol* 25, 29-35. <https://doi.org/10.3354/ab00653>

Simões, M.S., Heckler, G.S., Costa R.C., 2017. Reproductive period and recruitment of Penaeoidea shrimp on the southeastern Brazilian coast: implications for the closed season. *Crustaceana* 90, 1177-1192. <https://doi.org/10.1163/15685403-00003664>

Spaargaren, D.H., Haefner, P.A.J., 1994. Interactions of ovary and hepatopancreas during the reproductive cycle of *Crangon crangon* (L.). II. Biochemical relationships. *Journal of Crustacean Biology*. 14, 6-19. <https://doi.org/10.2307/1549050>

Tan-Fermin, J.D., 1991. Effects of unilateral eyestalk ablation on ovarian histology and oocyte size frequency of wild and pond-reared *Penaeus monodon* (Fabricius) broodstock. *Aquaculture* 93,77-86. [https://doi.org/10.1016/0044-8486\(91\)90206-M](https://doi.org/10.1016/0044-8486(91)90206-M)

Tan-Fermin, J.D., Pudadera R.A., 1989. Ovarian maturation stages of the wild giant tiger prawn, *Penaeus monodon* Fabricius. *Aquaculture*. 77, 229–242. [https://doi.org/10.1016/0044-8486\(89\)90205-6](https://doi.org/10.1016/0044-8486(89)90205-6)

Valenti, W. C., Hayd, L. A., Vetorelli, M. P., Martins, M. I. E. G., 2011. Economic analysis of amazon river prawn farming to the markets for live bait and juveniles in Pantanal, Brazil. *Bol. Inst. Pesca*. 37(2): 165-176. Available at https://www.pesca.sp.gov.br/boletim/index.php/bip/article/view/37_2_165-176

Valenti, W. C., Barros, H. P., Moraes-Valenti, P., Bueno, G. W., Cavalli, R. O., 2021. Aquaculture in Brazil: past, present and future. *Aquac. Rep.* 19: 2021, 100611. <https://doi.org/10.1016/j.aqrep.2021.100611>

Vidal, B.C., 1977. Acid glycosaminoglycans and endochondral ossification: microspectrophotometric evaluation and macromolecular orientation. *Cell Molecular Biology*. 22(01): 45- 64. Available at <https://pubmed.ncbi.nlm.nih.gov/606358/>

Wickins, J.F., Beard, T.W., Child, A.R., 1995. Maximizing lobster, *Homarus Gammarus* (L.), egg, and larval viability. *Aquaculture Research*. 26, 379–392. <https://doi.org/10.1111/j.1365-2109.1995.tb00927.x>

Worsmann, T.U., Barcelos, S.R., Ferri, A.C., 1976. Étude histologique de l’ovaire de *Penaeus paulensis* Pérez-Farfante, 1967. *Bol. Inst. Oceanogr.* 25(1): 43-54. <https://doi.org/10.1590/S0373-55241976000100003>

Wouters, R., Piguave, X., Bastidas, L., Calderon, J., Sorgeloos, P., 2001a. Ovarian maturation and haemolymphatic vitellogenic concentration of pacific white shrimp *Litopenaeus vannamei* (Boone) fed increasing levels of total dietary lipids and HUFA. *Aquaculture Research*, 32, 573–582. <https://doi.org/10.1046/j.1365-2109.2001.00580.x>

Wouters, R., Molina, C., Lavens, P., Calderon, J., 2001b. Lipid composition and vitamin content of wild female *Litopenaeus vannamei* in different stages of sexual

maturation. *Aquaculture*. 198, 307–323. [https://doi.org/10.1016/S0044-8486\(01\)00522-1](https://doi.org/10.1016/S0044-8486(01)00522-1)

Yamano, K., Qiu, G.F., Unuma, T., 2004. Molecular cloning and ovarian expression profiles of thrombospondin, a major component of cortical rods in mature oocytes of penaeid shrimp, *Marsupenaeus japonicus*. *Biol. Reprod.* 70, 1670–1678. <https://doi.org/10.1095/biolreprod.103.025379>

Yano, I., 1988. Oocyte development in the kuruma prawn *Penaeus japonicus*. *Marine Biology*, 99: 549-553. <https://doi.org/10.1007/BF00392562>

Yano, I., Chinzei, Y., 1987. The ovary is the site of vitellogenin synthesis in Kuruma prawn, *Penaeus japonicus*. *Comparative Biochemistry Physiology*. 86B, 213–218. [https://doi.org/10.1016/0305-0491\(87\)90280-X](https://doi.org/10.1016/0305-0491(87)90280-X)

Yano, I., Krol, R.M., Overstreet, R.M., Hawkins, W.E., 1996. Route of egg yolk protein uptake in the oocytes of kuruma prawn, *Penaeus japonicus*. *Marine Biology*. 125, 773-781.

Zara, F.J., Gaeta, H.H., Costa, T.M., Toyama, M.H., Caetano, F.H., 2011. The ovarian cycle histochemistry and its relationship with hepatopancreas weight in the blue crab *Callinectes danae* (Crustacea: Portunidae). *Acta Zool.* 94, 134-146. <https://doi.org/10.1111/j.1463-6395.2011.00537.x>

3.2 Capítulo II:

Métodos utilizados na identificação dos estágios de maturação ovariana macroscópico do *Xiphopenaeus kroyeri*: implicações na determinação da época de desova

Resumo

Uma avaliação precisa dos parâmetros populacionais relacionados à reprodução de camarões peneídeos é essencial para um manejo pesqueiro mais eficiente deste recurso de grande importância comercial no mundo. As amostragens dos espécimes de *Xiphopenaeus kroyeri* ocorreram em Lucena, Paraíba, Brasil (6°53'50 "S, 34°51'01 "W) durante o período de dezembro de 2016 a novembro de 2017. Todas as fêmeas foram avaliadas macroscopicamente, usando dois métodos diferentes. No primeiro método (Método I), o estágio de maturação foi avaliado macroscopicamente observando-se o ovário através do exoesqueleto, com o auxílio de luz artificial. No segundo método (Método II), o estágio de maturação foi avaliado macroscopicamente a partir da extração do ovário fresco; e sua morfologia foi observada, considerando o grau de turgidez e a aparência do tecido que reveste a gônada. Todas as amostras foram submetidas a análise histológica padrão. Foi avaliado o índice de concordância (%) através da fórmula: $IC (\%) = NC \times 100 / NTF$ para verificar qual método apresenta mais concordância com a análise histológica. O método II apresentou melhor índice de concordância com a análise histológica em relação ao método I, destacando a importância de observar as características morfológicas de uma fêmea-recém capturada, uma vez que a coloração dos ovários tende a se modificar ao longo do tempo. Ambos os métodos se apresentaram eficientes para identificar o estágio maduro, uma vez que 100% das amostras foram identificadas corretamente, destacando que ambos os métodos podem ser utilizados para identificar corretamente este estágio de maturação. O agrupamento dos estágios desovado e repouso em um único estágio pode ser considerado um grande problema, pois apresentam características e interpretações opostas do ponto de vista histológico, acarretando em sérios problemas nos meses de desova, bem como no pico de desova.

Palavras-chave: análise macroscópica, histologia, ovário, gestão.

1. Introdução

A avaliação das fases de desenvolvimento gonadal é uma etapa crucial para compreender a biologia reprodutiva de camarões peneídeos (CRISP et al., 2017). No campo da biologia pesqueira, a correta identificação da escala maturacional resulta em uma menor ambiguidade na classificação da fase de maturação dos ovários e, conseqüentemente, melhora as estimativas dos padrões reprodutivos (CRAVEIRO et al., 2022). Contudo, apesar da ampla utilização da avaliação da escala maturacional em camarões peneídeos, existem inúmeras divergências em relação ao número de estágios, bem como nas metodologias aplicadas na avaliação macroscópica dos ovários, o que pode gerar erros na classificação das fases de maturação, e conseqüentemente nas medidas de gestão.

De fato, a maioria dos estudos destinados à classificação da escala de maturação dos ovários em camarões peneídeos derivam de estudos destinados à desova em cativeiro para fins de produção de larvas de espécies comercialmente importantes. Nesse caso, os estágios ovarianos normalmente descritos são quatro: imaturo, em maturação, maturo e desovado (QUACKENBUSH, 1989; TAN-FERMIN e PUDADERA, 1989; PALACIOS et al., 1999; MEDINA et al., 1996; PEIXOTO et al., 2002, 2003). A previsão do momento da desova é fundamental e tem sido feita observando a coloração e formato através do exoesqueleto transparente do camarão. Após a identificação do estágio maturo, as fêmeas são transferidas para tanques de desova. Neste contexto, é evidente que reconhecer com precisão apenas o estágio maturo seja suficiente, uma vez que é fácil observar a cor e espessura do ovário através da carapaça transparente do camarão, facilitando a gestão dos reprodutores em cativeiro sem ter que os sacrificar.

A visualização da coloração dos ovários através do exoesqueleto, embora apresente várias vantagens para a gestão dos reprodutores na aquicultura, pode não ser uma avaliação muito criteriosa na classificação da maturação dos ovários para estabelecer parâmetros populacionais precisos de fêmeas selvagens. Um exemplo disto são as inúmeras classificações dos estágios de maturação ovariano, os quais descrevem de quatro e seis estágios (VOGT et al., 1989; TAN-FERMIN, 1991; MEDINA et al., 1996; QUINTERO e GRACIA, 1998; PALACIOS et al., 1999; AYUB e AHMED, 2002; PEIXOTO et al., 2003; SILVA et al., 2016; BOLOGNINI et al., 2017; PEIXOTO et al., 2018; CRAVEIRO et al., 2019; GARCIA et al., 2021; CRAVEIRO et al., 2022). Além disso, as características morfológicas dos ovários frescos se modificam rapidamente. Isto ocorre especialmente com as características que diferenciam os

estágios imaturo, desovado e repouso, que são de difícil distinção através do exoesqueleto, como têm sido relatados em diversos estudos voltados para a dinâmica reprodutiva (DUMONT e D'INCAO, 2004; GONÇALVES et al., 2009; SILVA et al., 2016; LOPES et al., 2017; CRAVEIRO et al., 2019; GARCIA et al., 2021).

A compreensão das relações entre os estágios de maturação gonadal e os parâmetros populacionais relacionados com a reprodução fornece informações para o estabelecimento de um plano de gestão pesqueiro que permita a captura racional e sustentável das unidades populacionais de camarão. No entanto, existem lacunas no conhecimento da biologia reprodutiva de muitas espécies, as quais podem ser ainda mais acentuadas pela qualidade dos dados ou pelos métodos utilizados para a sua obtenção (PEIXOTO et al., 2011; CRISP et al., 2017). Recentemente, Craveiro et al. (2022) observaram para o *Penaeus subtilis* que a extração do ovário combinada com a avaliação morfológica através da coloração, aparência e textura dos ovários frescos tornou possível diferenciar macroscopicamente os estágios desovado e repouso, o que foi posteriormente confirmado com a análise histológica. Estes autores pontuaram que a aplicação dessa metodologia poderia melhorar as estimativas da época reprodutiva, período de desova e tipo de desova.

Neste sentido, o objetivo deste estudo foi comparar as técnicas descritas acima, testando sua concordância na determinação dos estágios de maturação gonadal quando comparando a análise histológica. Além disso, pretende-se observar se haveriam mudanças nas estimativas de período reprodutivo e época de desova utilizando cada uma destas técnicas.

2. Material e métodos

2.1 Área de estudo e transporte das amostras para o laboratório

A amostragem ocorreu em Lucena, Paraíba, Brasil (6°53'50 "S, 34°51'01 "W) durante o período de dezembro de 2016 a novembro de 2017. Foram realizados dois arrastos mensais utilizando rede de arrasto de praia com auxílio de uma embarcação não-motorizada empregada por pescadores artesanais da região. Os arrastos foram realizados a partir de 500 metros (profundidade de 6 metros até a zona de surf) e puxados em direção à costa. Após a amostragem, os espécimes foram armazenados em gelo e transportados para o laboratório para posterior análise.

2.2 Avaliação morfométrica e análise macroscópica dos ovários

As fêmeas de *Xiphopenaeus kroyeri* (n=1.289) foram sexadas com base na presença do tégico. O comprimento total (CT), o comprimento do cefalotórax (CC) e o peso total úmido (PT) foram medidos com paquímetro digital (cm) e balança de precisão (000,1 g). O desenvolvimento dos ovários foi determinado com base na morfologia e na cor. Todas as fêmeas foram avaliadas macroscopicamente por dois métodos. No método I, o estágio de maturação foi avaliado macroscopicamente observando-se o ovário através do exoesqueleto, com o auxílio de luz artificial. A cor do ovário foi comparada a um catálogo cromático amplamente disponível (Pantone Matching System, Coated Simulation, Pantone, Carlstadt, NJ, EUA) para estabelecer um ponto de referência cromático. No método II, o estágio de maturação foi avaliado macroscopicamente a partir da extração do ovário fresco, cuja morfologia foi observada considerando o grau de turgidez e a aparência do tecido que reveste a gônada. A cor do ovário fresco também foi comparada com o mesmo catálogo cromático do método I.

2.2 Análise histológica

As fêmeas foram dissecadas para análise histológica dos ovários (n=1.289). Os ovários foram dissecados da cavidade dorsal do corpo, e foram retirados fragmentos (0,5 cm) da porção mediana, fixados em solução salina Davidson por 24 horas e transferidos para 70% de álcool para conservação. As seções do ovário foram desidratadas em séries ascendentes de álcool (80, 90%, 95% e 100%), clarificadas em xilol e embebidas em parafina. As lâminas foram seccionadas em 5 µm usando um micrótomo rotativo (Leica RM2145, Leica Microsystems, Alemanha).

As lâminas foram coradas com hematoxilina de Harris e contra coradas com eosina-floxina para visualizar o estágio de desenvolvimento ovariano de cada amostra. As lâminas foram observadas em um microscópio óptico (Leica DM500) equipado com uma câmera digital (Leica ICC50HD). As fotomicrografias das lâminas foram digitalizadas com o software Leica com objetivas de 4× a 100× de ampliação.

2.3 Análise de dados

O índice de concordância dos dois métodos foi calculado a partir da proporção de respostas corretas quanto à concordância entre o método I (observação do estágio através da carapaça transparente) em relação à análise histológica, bem como o método II (extração do ovário fresco e morfologia e padrão de coloração) em relação à análise histológica. Esta proporção foi obtida utilizando a fórmula: $IC (\%) = NC \times 100 / NTF$, onde IC% é o índice de concordância, NC é o número total de concordâncias, NTF é o

número total de fêmeas amostradas. O índice de erro foi obtido a partir da seguinte fórmula, $IE (\%) = NTE \times 100 / NTF$, onde IE é o índice de erro, NTE é o número total de erros e NTF é o número total de fêmeas amostradas.

Para a classificação dos estágios de maturação gonadal, os dados foram agrupados em diferentes estágios de maturação com base na presença da fase celular mais desenvolvida. A classificação histológica dos estágios de maturação gonadal para o método I utilizou a escala definida por Lopes et al. (2014). Para o método II, utilizou-se a classificação histológica seguindo Craveiro et al. (2022), a qual foi adaptada para a espécie. O período reprodutivo foi determinado com base na proporção mensal dos estágios de maturação ovariano, enquanto a época de desova foi avaliada usando a frequência relativa mensal do estágio desovado.

3. Resultados

O método I permitiu identificar quatro estágios macroscópicos de maturação gonadal apresentando coloração distintas. Os estágios I (imaturo) e III (maturo) obtiveram apenas uma coloração de ovário, translúcido e verde escuro (Pantone 5757 PC), respectivamente. Para o estágio II foi observado duas cores, verde claro (Pantone 586 PC) e verde médio (Pantone 385 PC). Da mesma forma, para o estágio IV foi observada as cores amarelo-claro (Pantone 602 PC) e translúcido (Figura 1a).

O método II, por sua vez, permitiu a identificação de seis estágios de maturação. O estágio I (imaturo) e o estágio VI (repouso) apresentaram a coloração translúcida. O estágio II (em maturação inicial) apresentou a cor verde claro (584 PC), estágio III (em maturação avançada) apresentou a cor verde médio (384 PC), estágio IV (Maturo) apresentou a cor verde escuro (384 PC) e o estágio V (desovado) apresentou a cor verde claro (379 PC), conforme a Figura 1b.




Figura 1. Escala maturacional macroscópica do *Xiphopenaeus kroyeri*: a) escala maturacional macroscópica obtida a partir da visualização dos ovários através do exoesqueleto (Método I) mostrando as cores de ovário mais frequentes de acordo com o catálogo Pantone (I: imaturo, II: em maturação, III: maturo e IV: desovado); b) escala maturacional macroscópica obtida a partir da extração, visualização e observação da morfologia dos ovários frescos (Método II) mostrando as cores dos ovários mais frequentes de acordo com o catálogo Pantone (I: imaturo, II: em maturação inicial, III:

em maturação avançada, IV: maturo, V: desovado, VI: repouso). Legenda: cor translúcida (T).

A análise histológica das fêmeas observadas pelo método I possibilitou a identificação de quatro estágios de maturação: imaturo (I) com presença de ovócitos pré-vitelogênicos; em maturação (II) com presença de ovócitos em vitelogênese primária e secundária; maturo (III) com presença de ovócitos maduros apresentando vesículas por todo o citoplasma; desovado (IV) apresentando ovócitos pré-vitelogênicos, ovócitos atrésicos e folículos pós-ovulatório (Figura 2a).

O método II, por sua vez, possibilitou identificar seis estágios de maturação: imaturo (I) com presença de ovócitos pré-vitelogênicos; em maturação inicial (II) com presença de ovócitos em vitelogênese primária; em maturação avançada (III) com presença de ovócitos em vitelogênese secundária; maturo (IV) com presença de ovócitos maduros apresentando vesículas por todo o citoplasma; desovado (V) ovócitos pré-vitelogênicos, ovócitos atrésicos e folículos pós-ovulatório e repouso (VI) com presença de ovócitos pré-vitelogênicos, como pode ser observado na Figura 2b.

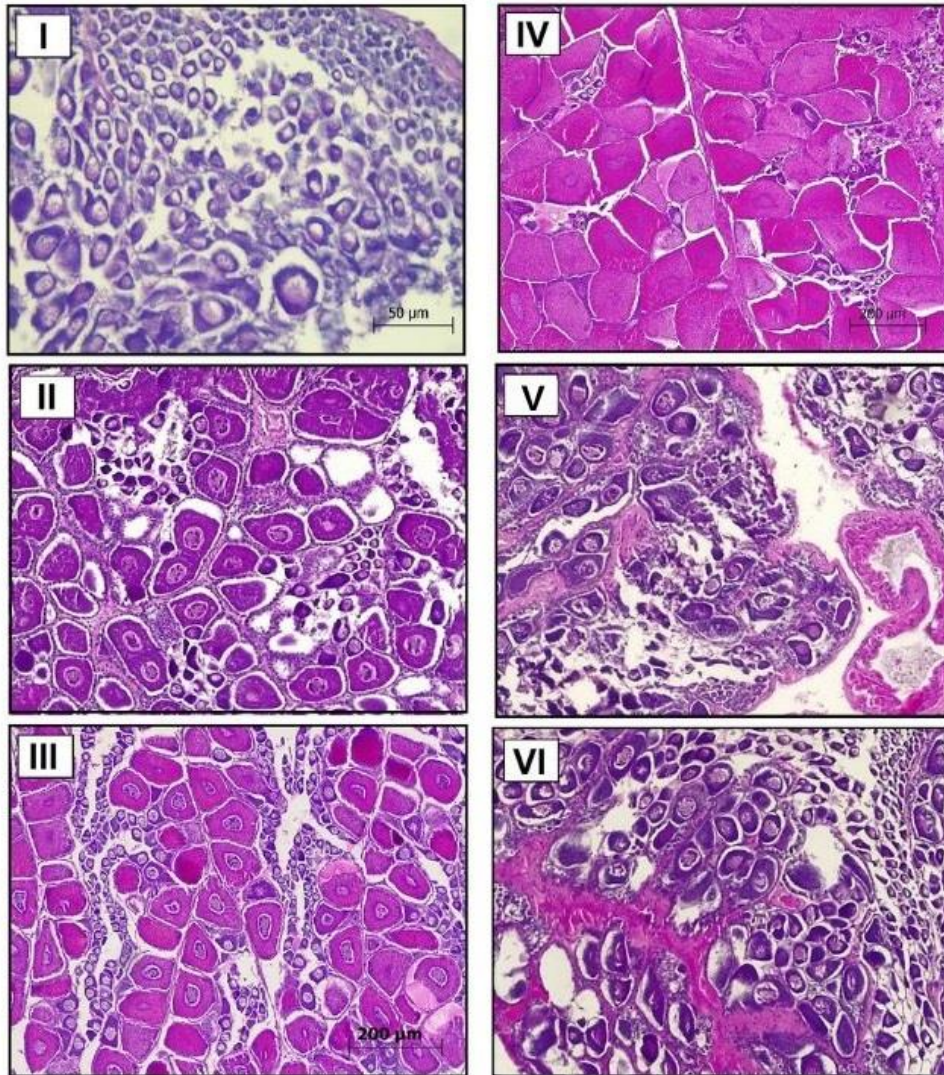


Figura 2. Cortes histológicos dos ovários de *Xiphopenaeus kroyeri* mostrando a escala maturacional através do método I representados pelas figuras: I (estágio imaturo), II (em maturação), IV (estágio maturo) e V (Estágio desovado); escala maturacional através do método II representadas pelas figuras: I (imaturo), II (em maturação inicial), III (em maturação avançada), IV (maturo), V (desovado), VI (repouso).

O índice de concordância (%) mostrou que a extração dos ovários frescos para avaliação macroscópica (método II) resulta em um maior índice de concordância (89,61%) quando comparado com o método I, em que ocorre apenas a visualização dos ovários através da carapaça de camarão (55,6%) (Tabela 1).

No método I, do total de 156 amostras identificadas histologicamente como estágio imaturo, 42 (26,92%) amostras foram identificadas de forma errada como estágio desovado; 352 amostras identificadas como estágio em maturação, 174 (49,4%)

foram identificados de forma equivocada como estágio maturo (Tabela 1). Do total de 155 amostras identificadas como estágio maturo houve 100% de acertos; dentre as 626 amostras determinadas histologicamente como desovadas, 501 amostras foram identificadas de forma equivocada, sendo 430 (68,69%) amostras identificadas como estágio imaturo e 71 (11,34%) das amostras identificadas como o estágio em maturação.

No método II, do total de 156 amostras identificadas histologicamente como estágio imaturo, apenas 18 amostras (11,5%) amostras foram identificadas de forma errada como estágio repouso; 194 amostras identificadas como o estágio em maturação inicial, 9 (4,63%) foram identificados de forma equivocado como estágio desovado, conforme pode ser observado na Tabela 1. O estágio de maturação avançado (n=158), 14 (8,8%) foram identificados de forma equivocada como estágio maturo; As amostras identificadas como estágio maturo (n=155) obtiveram 100% de acertos em relação a análise histológica. Do total de 122 amostras determinadas histologicamente como desovadas, 4 (3,27%) amostras foram identificadas de forma equivocada como em maturação inicial e 3 (2,4%) como estágio repouso. Do total de 504 amostras determinadas histologicamente como repouso, 86 (17,06%) amostras foram identificadas de forma equivocada como imaturo.

Tabela 1. Índice de concordância (%), número de acertos, índice de erros, e número de erros entre os métodos I (visualização dos ovários através do exoesqueleto) e II (extração, visualização e observação da morfologia dos ovários frescos) de avaliação macroscópica quando comparados com a análise histológica dos estágios de maturação ovariano do camarão *Xiphopenaeus kroyeri*.

Estágio	Índice de concordância (%)	Nº de acertos	Índice de erro (%)	Nº de erros	Nº total
Método I					
I	73,08	114	26,92	42	156
II	49,60	178	49,40	174	352
III	100,00	155	0,00	0	155
IV	18,93	125	81,03	501	626
Geral	89,61				
Método II					
I	88,50	138	11,50	18	156
II	95,37	185	4,63	9	194
III	91,20	144	8,80	14	158
IV	100,00	155	0,00	0	155
V	94,33	115	5,67	7	122

VI	82,94	418	17,06	86	504
Geral	55,60				

Com base na proporção mensal dos estágios de maturação ovariano foi obtido o período reprodutivo utilizando a escala macroscópica e histológica para ambos os métodos (Figura 3a e b), bem como foi possível identificar a época de desova a partir a frequência relativa mensal do estágio desovado. Utilizando ambos os métodos, o período de maior atividade reprodutiva ocorreu de outubro a março. No método I, não há fêmeas maduras de junho a setembro e as desovas ocorrem o ano inteiro (exceto janeiro), com maior pico de abril a setembro, caracterizando um ciclo contínuo (Figura 3a). No método II, o pico de desova ocorre em abril e maio, caracterizando um ciclo descontínuo devido à ausência de desovas de junho a setembro. O período de repouso, em que os ovários das fêmeas não estão em desenvolvimento, ocorre de junho a setembro (Figura 3b).

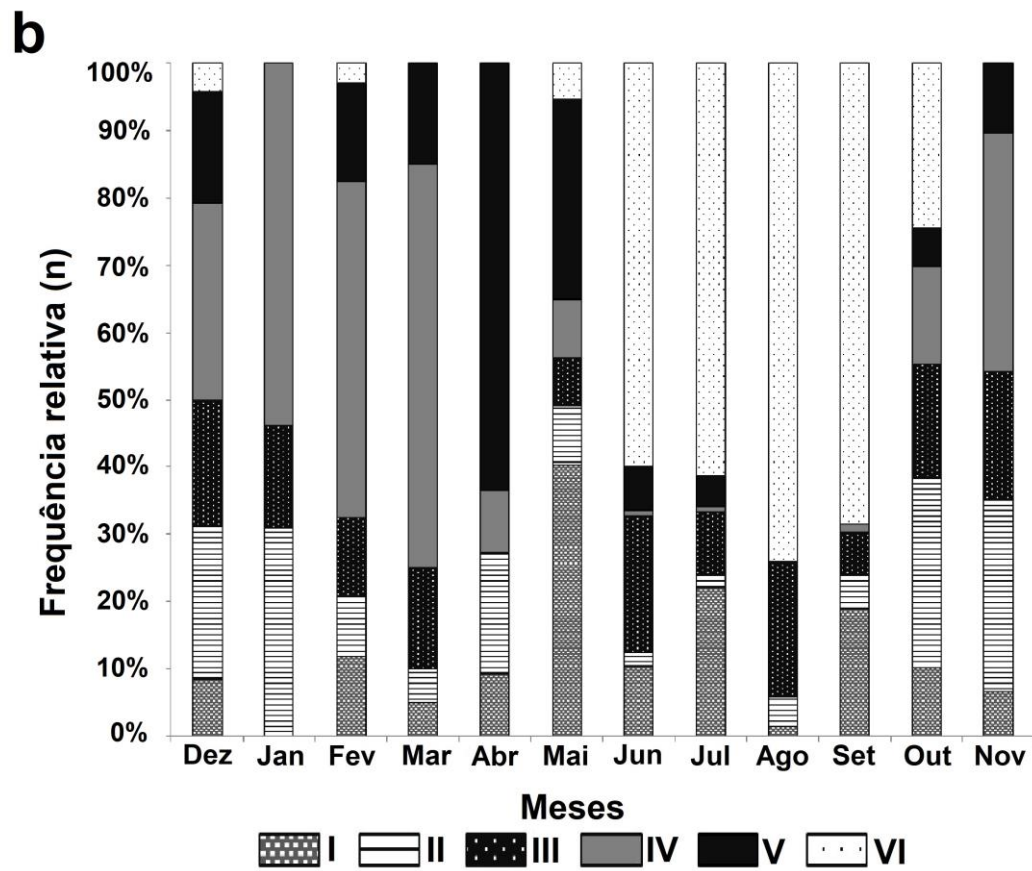
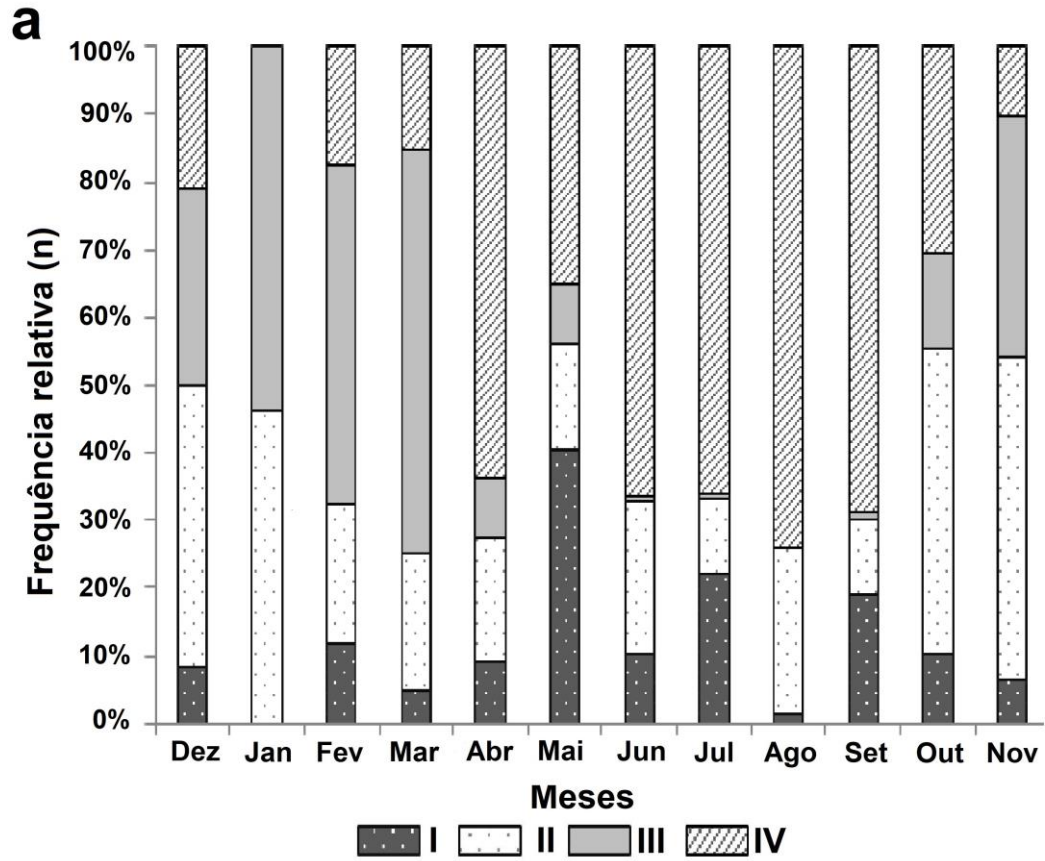


Figura 3. Período reprodutivo do camarão *Xiphopenaeus kroyeri*: a) estimado a partir da visualização dos ovários através do exoesqueleto (método I) (I: imaturo, II: em maturação, III: maturo e IV: desovado); b) estimado a partir da extração, visualização e observação da morfologia dos ovários frescos (método II) (I: imaturo, II: em maturação inicial, III: em maturação avançada, IV: maturo, V: desovado, VI: repouso).

4. Discussão

A classificação macroscópica e histológica dos estágios de desenvolvimento gonadal tem sido utilizada em conjunto cada vez mais para confirmar e validar as escalas maturacionais das espécies a fim de minimizar os erros nas estimativas de maturidade (QUINTERO e GRACIA, 1998; LOPES et al., 2014; SILVA et al., 2016; PEIXOTO et al. 2018; CRAVEIRO et al., 2022; RIOS et al., 2022), que são úteis tanto para a gestão pesqueira como para o manejo de reprodutores em cativeiro.

O índice de concordância permitiu observar uma porcentagem maior de concordância da avaliação macroscópica do método II (89,61%) do que no método I (55,6%) em relação à análise histológica, destacando a importância de observar as características morfológicas de uma fêmea-recém capturada, uma vez que a coloração dos ovários tende a se modificar ao longo do tempo, como também foi observado por Craveiro et al. (2022) para *Penaeus subtilis*. Crisp et al. (2017) e Quintero e Gracia (1998) tiveram dificuldades para avaliar os estágios desovado e imaturo através do exoesqueleto devido ao escurecimento do exoesqueleto. Estes autores só conseguiram distinguir aqueles estágios com base na análise histológica.

As avaliações macroscópicas do método II apresentaram uma escala maturacional mais consistente em relação ao método I, pois apresentou apenas uma cor para cada estágio correspondente. A classificação macroscópica do desenvolvimento gonadal utilizando uma escala de coloração é uma metodologia amplamente utilizada, sendo uma alternativa prática e está intimamente relacionada ao desenvolvimento e organização das células germinativas que constituem o ovário (DUMONT e D'INCAO, 2004; DUMONT et al. 2007). Apesar disso, Quintero e Gracia (1998) e Peixoto et al. (2003) destacaram que esta análise pode gerar dúvidas, uma vez que é possível observar diferentes colorações para um mesmo estágio de maturação. Em nosso estudo, observamos que os ovários do estágio II classificados pelo método I, que apresentaram cores diferentes na escala, possuíam células germinativas em diferentes fases de vitelogênese. Os ovários na cor verde claro (Pantone 586 PC) apresentavam ovócitos

em vitelogênese primária, já os na cor verde médio (Pantone 385 PC) apresentavam ovócitos em vitelogênese secundária. Além disso, estes ovócitos não ocorriam simultaneamente no mesmo ovário. Este fato também foi evidenciado no índice de concordância, pois, das 352 amostras identificadas como estágio em maturação, 174 (49,4%) foram identificados de forma equivocada como estágio maturo. Acreditamos que pelo fato de alguns ovários possuírem um tom de verde mais escuro do que outros, este fato possa ter gerado dúvidas para o observador quanto a estimativa de maturidade gerando diferentes interpretações.

O mesmo ocorreu em relação ao estágio IV do método I, que apresentou duas colorações, amarelo claro (Pantone 602 PC) e translúcido. Histologicamente são ovários distintos. Os ovários amarelos apresentavam ovócitos pré-vitelogênicos, ovócitos atrésicos e folículos pós-ovulatórios, enquanto os ovários translúcidos apenas apresentavam ovócitos pré-vitelogênicos. O índice de concordância no método I indicou que das 626 amostras determinadas histologicamente como desovadas, 430 foram identificadas como estágio imaturo, que seriam os ovários de coloração translúcida, e 71 identificadas como o estágio em maturação, que apresenta coloração amarelo-claro (Pantone 602 PC). Este fato sugere que os ovários desovados identificados erroneamente como imaturos se assemelham mais histologicamente ao estágio repouso determinado no método I, do que propriamente ao desovado, decorrente da ausência de ovócitos atrésicos e folículos pós-ovulatórios. Neste sentido, para ambos os casos citados acima, recomendamos que estes estágios sejam separados na escala maturacional para que se possa ter concordância com a análise histológica.

Ambos os métodos se apresentaram eficientes para identificar o estágio maturo, uma vez que 100% das amostras foram identificadas corretamente. Crisp et al. (2017) utilizaram o método I e observaram que as gônadas maduras eram consideravelmente mais fáceis para distinguir externamente através do exoesqueleto em fêmeas de *Metapenaeus dalli*. Apesar da subjetividade na definição das cores e das limitações de seu uso, este método é uma ferramenta importante que pode ser utilizada no manejo de reprodutores em cativeiro (ALFARO-MONTOYA, 2013; CEBALLOS VÁZQUEZ et al., 2003), uma vez que se mostraram eficientes na identificação de indivíduos maturos e sua coleta para realizarem a desova controlada.

Ambos os métodos de classificação analisados neste estudo resultaram em estimativas do período de maior atividade reprodutiva nos meses de outubro a março. Este fato sugere que para a identificação do estágio maturo ambos podem ser utilizados,

o que corrobora também com seus índices de concordância de 100% de acertos na identificação desse estágio. No entanto, as diferenças entre os métodos se tornam evidentes e preocupantes quando são utilizados para estimar o pico de desovas. Enquanto o método I indica a ocorrência de desovas ao longo do ano, caracterizando um ciclo contínuo, com maior pico de desova de abril a setembro, o método II apresenta ciclo descontínuo, com pico de desova apenas em abril e maio, cessando a atividade reprodutiva completamente de junho a setembro. O motivo dessa diferença decorre do agrupamento dos estágios repouso e desovado no método I, acarretando em uma interpretação completamente oposta da época de desova. Reis Jr. et al. (2017) utilizaram a metodologia de análise macroscópica do método I e relataram que o período reprodutivo era contínuo para *X. kroyeri*, uma vez que foram encontradas fêmeas em estágio maturo e desovado durante todo o ano na costa de Sergipe, nordeste do Brasil. O agrupamento dos estágios desovado e repouso em um único estágio pode ser considerado um erro, pois apresentam características e interpretações opostas do ponto de vista reprodutivo. O estágio desovado significa uma intensa atividade reprodutiva devido à desova recente, enquanto o estágio de repouso indica ausência de qualquer tipo de atividade reprodutiva. Em outras palavras, o agrupamento dos dois estágios pode levar a sérios problemas nas estimativas da época de desova.

As implicações do agrupamento dos estágios desovado e repouso podem ser desastrosas se determinarmos medidas de manejo tomando como base que o ciclo reprodutivo é contínuo, como observado no método I (Figura 3a). Supostamente, se aplicássemos um período de defeso tomando como base a determinação do pico de desova, este ocorreria exatamente no período em que as fêmeas não apresentam atividade reprodutiva (estariam em repouso reprodutivo), ou seja, não causaria efeito algum sobre a população a tomada dessa medida de gestão (Figura 3a). Reis Jr. et al. (2017) pontuaram a existência de um pico de desova em agosto-setembro para *X. kroyeri* em Sergipe. Os autores se basearam na observação das fêmeas maduras e desovadas para caracterizar os picos de desovas, o que coincide substancialmente com a época de repouso das fêmeas (julho a setembro) em nosso estudo utilizando o método II para obter as estimativas. Apesar da problemática associada a este agrupamento, sua ocorrência é comum, como pode ser observado em diversos estudos sobre a reprodução de camarões peneídeos: Quintero e Gracia (1998), Palacios et al. (1999), Ayub e Ahmed (2002), Peixoto et al. (2003, 2018), Campos et al. (2009), Martins et al. (2013), Silva et

al. (2016), Lopes et al. (2017), Bolognini et al. (2017), Craveiro et al., (2019) e Garcia et al. (2021).

Foi possível observar no presente estudo que o método II apresentou melhor índice de concordância com a análise histológica em relação ao método I, destacando a importância de observar as características morfológicas de uma fêmea-recém capturada, uma vez que a coloração dos ovários tende a se modificar ao longo do tempo. As avaliações macroscópicas do método II apresentaram uma escala maturacional mais consistente em relação ao método I, devido ao fato de ter tido apenas uma cor para cada estágio de maturação correspondente. Ambos os métodos se apresentaram eficientes para identificar o estágio maturo, uma vez que 100% das amostras foram identificadas corretamente, destacando que ambos os métodos podem ser utilizados no manejo de reprodutores em cativeiro. O agrupamento dos estágios desovado e repouso em um único estágio pode ser considerado um problema, pois apresentam características e interpretações opostas do ponto de vista histológico, acarretando erros nas estimativas de época de desova. Embora o método II tenha apresentado melhores índices de concordância em relação ao método I, é necessário um prévio conhecimento sobre a reprodução da espécie e

Os resultados obtidos no presente estudo contribuem para o aprimoramento das técnicas empregadas no manejo de reprodutores em cativeiro e para o estabelecimento de medidas de gestão para a pesca de camarões peneídeos.

5. Referências bibliográficas

ALFARO-MONTOYA, J. Descripción histológica de la oogenesis y espermatogénesis del camarón de cultivo *Litopenaeus vannamei*. **Revista de Biología Marina y Oceanografía**, 48(2), 335–34, 2013.

AYUB, Z.; AHMED, M. A. Description of the ovarian development stages of penaeid shrimp from the coast of Pakistan. **Aquaculture Research**, v. 33, p.767-776, 2002.

BOLOGNINI, L.; DONATO, F.; LUCCHETTI, A.; OLIVOTTO, I.; TRUZZI, C.; RANDAZZO, B.; ANTONUCCI, M.; ILLUMINATI, S.; GRATI, F. A multidisciplinary approach to study the reproductive biology of wild prawns. **Scientific Reports**, vol. 7, no. 1, pp. 16781, 2017.

CAMPOS, B.R.; DUMONT, L.F.C.; D'INCAO, F.; BRANCO, J.O. Ovarian development and length at first maturity of the sea-bob-shrimp *Xiphopenaeus kroyeri* (Heller) based on histological analysis. **Nauplius**, vol. 17, no. 1, pp. 9-12, 2009.

CRAVEIRO, C.; PEIXOTO, S.; SILVA, E.; CASTRO-NETO, H.; EDUARDO, L.; LIRA, A.; FRÉDOU, F. L.; SOARES, R. Reproductive dynamics of the white shrimp *Litopenaeus schmitti* (Burkenroad, 1936) in a beach seine fishery in northeastern Brazil. **Invertebrate Reproduction & Development**, 63(2), 111–121, 2019.

CRAVEIRO, C.; SOARES, R.; CASTRO-NETO, H.; SILVA, E. F.; SOARES, A.; DE OLIVEIRA, P. G; PEIXOTO, S. Ovarian maturation of *Penaeus subtilis* (Decapoda: Penaeidae): A new insight to describe oocyte development and somatic structures. **Acta Zoologica**, 2022.

CRISP, J.A.; D'SOUZA, M.L.D.F.; TWEEDLEY, J.R.; PARTRIDGE, G.J.; MOHEIMANI, N.R. Quantitative determination of ovarian development in penaeid prawns (Decapoda: Penaeidae). **Journal of Crustacean Biology**, 37(1): 81–89, 2017 doi: 10.1093/jcbiol/ruw001.

DUMONT, L. F. C.; D'INCAO, F. Estágios de desenvolvimento gonadal de fêmeas do camarão-barbaruça (*Artemesia longinaris* - Decapoda: Penaeidae). **Iheringia, Série Zoologica**, 94(4), 389–393, 2004.

DUMONT, L.F.C.; D'INCAO, F.; SANTOS, R.A.; MALUCHE, S.; RODRIGUES, L.F. Ovarian development of wild pink prawn (*Farfantepenaeus paulensis*) females in northern coast of Santa Catarina State, Brazil. **Nauplius**, 15, 65–71, 2007.

GARCIA, R.C.P.; CRAVEIRO, C.F.F.; BERNABÉ, C.V., SILVA, M.A.; ARIDE, P.H.R.; OLIVEIRA, A.T.; GONÇALVES, F.R.S.C.; SANTANDER-NETO, J.; LAVANDER, H.D.; FAGGIO, C. Gonadal development of females of the white shrimp *Penaeus schmitti* (Burkenroad, 1936) caught in southeastern Brazil. **J. Mar. Sci. Eng.** 29, 653, 2021.

GONÇALVES, S.M.; SANTOS, J.L.; RODRIGUES, E.S. Estágios de desenvolvimento gonadal de fêmeas do camarão-branco *Litopenaeus schmitti* (Burkenroad, 1936),

capturadas na região marinha da Baixada Santista, São Paulo. **Rev. Ceciliansa**, 1, 96–100, 2009.

LOPES, D. F. C.; PEIXOTO, S.; FRÉDOU, F. L. Population biology of seabob-shrimp *Xiphopenaeus kroyeri* (Heller, 1862) captured on the south coast of Pernambuco State, northeastern Brazil. **Braz. J. Oceanogr.**, v. 62, p. 331-340, 2014.

MARTINS, A.S.; PINHEIRO, H.T.; LEITE-JÚNIOR, N.O. Biologia Reprodutiva do Camarão Sete-barbas no Litoral Centro Sul e Sul do Espírito Santo, Brasil. **Boletim do Instituto de Pesca**, vol. 39, no. 3, pp. 205-215, 2013.

MEDINA, A.; VILA, Y.; MOURENTE, G.E.; RODRÍGUEZ, A. A comparative study of the ovarian development in wild and pond-reared shrimp, *Penaeus kerathurus* (Forsk., 1775). **Aquaculture**, vol. 148, no. 1, pp. 63-75, 1996.

PALACIOS, E.; RODRIGUES-JARAMILLO, C.; RACOTTA, I.S. Comparison of ovary histology between different-sized wild and pond-reared shrimp *Litopenaeus vannamei* (*Penaeus vannamei*). **Invertebrate Reproduction and Development**, vol. 35, no. 3, pp. 251-259, 1999.

PEIXOTO, S.; CALAZANS, N.; SILVA, E. F.; NOLE, L.; SOARES, R.; FREDOU, F. L. Reproductive cycle and size at first sexual maturity of the white shrimp *Litopenaeus schmitti* (Burkenroad, 1936) in northeastern Brazil. **Latin American Journal of Aquatic Research**, v. 46, n. 1, p. 1-9, 2018.

PEIXOTO, S.; CAVALLI, R. O.; D'INCAO, F.; MILACH, Â. M.; WASIELESKY, W. Ovarian maturation of wild *Farfantepenaeus paulensis* in relation to histological and visual changes. **Aquaculture Research**, 34(14), 1255-1260, 2003.

PEIXOTO, S.; CAVALLI, R.O.; D'INCAO, F.; WASIELESKY, W.; AGUADO, N. Description of reproductive performance and ovarian histology of wild *Farfantepenaeus paulensis* from shallow waters in southern Brazil. **Nauplius**, v. 10, p. 149-153, 2002.

PEIXOTO, S.; WASIELESKY, W; CAVALLI, R. O. Broodstock maturation and reproduction of the indigenous pink shrimp *Farfantepenaeus paulensis* in Brazil: An updated review on research and development. **Aquaculture**, v. 315, p. 9-15, 2011.

QUACKENBUSH, L.S. Vitellogenesis in the shrimp, *Penaeus vannamei*: in vitro studies of the isolated hepatopancreas and ovary. **Comp. Biochem. Physiol.** 94, 253–261, 1989.

QUINTERO, M.E.S.; GRACIA, A. Stages of gonadal development in the spotted pink shrimp *Penaeus brasiliensis*. **J. Crustac. Biol.** 18 (4), 680–685, 1989.

RIOS, A.S.; SHINOZAKI-MENDES, R.A.; SANTANA, J.L.; SOUZA-FILHO, J.F. Ovarian development of the crab *Eriphia gonagra* (Fabricius, 1981) (Decapoda: Brachyura: Eriphiidae) in northeastern Brazil. **J. Crustac. Biol.** vol. 42, no. 1, pp. 1-11, 2022. <https://doi.org/10.1093/jcbiol/ruac040>.

SILVA, E. F.; CALAZANS, N.; NOLÉ, L.; CASTELO-BRANCO, T.; SOARES, R., GUERRA, M. M. P.; FRÉDOU, F. L.; PEIXOTO, S. Reproductive dynamics of the southern pink shrimp *Farfantepenaeus subtilis* in northeastern Brazil. **Aquatic Biology** (Print), 25, 29–35, 2016.

TAN-FERMIN, J. D. Effects of unilateral eyestalk ablation on ovarian histology and oocyte size frequency of wild and pond-reared *Penaeus monodon* (Fabricius) broodstock. **Aquaculture**, 93(1), 77–86, 1991.

TAN-FERMIN, J.D., PUDADERA, R.A. Ovarian maturation stages of the wild giant tiger prawn, *Penaeus monodon* Fabricius. **Aquaculture**. 77, 229–242, 1989.

VOGT, G.; QUINTIO, E.T.; PASCUAL, F.P. Interaction of the midgut gland and the ovary in vitellogenesis and consequences for the breeding success: a comparison of unablated and ablated spawners of *Penaeus monodon*. In: DE PAUW, J.N., ACKEFORS, H., WILKINS, N.E. eds. **Aquaculture: A biotechnology in progress**. European Aquaculture Society: Bredene, pp. 581-592, 1989.

3.3 Capítulo III: artigo submetido em 26 de abril de 2022 e sendo considerado para a publicação na Revista Fisheries Research.

Fisheries Research
Ovarian maturation stages, size at maturity, spawning type and reproductive cycle of
Seabob shrimp *Xiphopenaeus kroyeri* (Decapoda, Penaeidea)
 --Manuscript Draft--

Manuscript Number:	
Article Type:	Research Paper
Keywords:	histology; ovarian development; reproduction; shrimp fishery
Corresponding Author:	Cecilia Fernanda Farias Craveiro, M.Sc Universidade Federal Rural de Pernambuco Recife, Pernambuco BRAZIL
First Author:	Cecilia Fernanda Farias Craveiro, M.Sc
Order of Authors:	Cecilia Fernanda Farias Craveiro, M.Sc Hildemário Castro-Neto Emanuel F. Silva, PhD Andrey Soares, Master of Science Alex Souza Lira, PhD Leandro Nolé Eduardo, PhD Flávia Lucena Frédou, PhD Roberta Soares, PhD Sílvia Peixoto, PhD
Manuscript Region of Origin:	BRAZIL
Abstract:	<p><i>Xiphopenaeus kroyeri</i> is a fishery resource of high economic, social and cultural importance on the Brazilian coast. Here we investigate the ovarian maturation stages, size at maturity, spawning type and reproductive cycle of the Seabob shrimp <i>X. kroyeri</i> caught in northeast Brazil. A total of 2,538 shrimps (1,289 females and 1,249 males) were collected through artisanal fisheries and macroscopically analyzed for one year. For ovarian histological analysis, 618 females were randomly selected and were classified into six stages based on macroscopic and histological analysis: immature, early developing, advanced developing, ripe, spent, and resting. The spent and resting stages, which have been grouped in reproductive studies of penaeids shrimp, were separated for the first time. Although cortical crypts were not present in the periphery of mature oocytes cytoplasm, we observed vesicles accumulated in the cytoplasm of these cells. The histological analysis showed oocytes with synchronous development presenting total spawning. The mean length at maturity (CL50) for females was 1.3 cm CL. The reproductive cycle was classified as seasonal for females, with greater ovarian maturity and gonadosomatic index from October to March. The spawning peak occurs during the period of highest rainfall, with a higher percentage of spent females. Our findings suggest that spent females also need to be monitored to establish management measures for the conservation of the species, and not just ripe females, since mature ovaries do not guarantee that they will spawn. These findings may be useful for the sustainable management of commercial penaeid fisheries.</p>
Suggested Reviewers:	Guadalupe Fabiola Arcos-Ortega, PhD researcher, Centro de investigaciones biológicas del noroeste farcos04@cibnor.mx Jason A. Crisp, PhD researcher, Murdoch University School of Veterinary and Life Sciences j.crisp@murdoch.edu.au Matthew D. Taylor, PhD researcher, The Port Stephens Fisheries Institute: Port Stephens Fisheries Centre matt.taylor@dpi.nsw.gov.au

Ovarian maturation stages, size at maturity, spawning type and reproductive cycle of Seabob shrimp *Xiphopenaeus kroyeri* (Decapoda, Penaeidea)

Abstract

Xiphopenaeus kroyeri is a fishery resource of high economic, social and cultural importance on the Brazilian coast. Here we investigate the ovarian maturation stages, size at maturity, spawning type and reproductive cycle of the Seabob shrimp *X. kroyeri* caught in northeast Brazil. A total of 2,538 shrimps (1,289 females and 1,249 males) were collected through artisanal fisheries and macroscopically analyzed for one year. For ovarian histological analysis, 618 females were randomly selected and were classified into six stages based on macroscopic and histological analysis: immature, early developing, advanced developing, ripe, spent, and resting. The spent and resting stages, which have been grouped in reproductive studies of penaeids shrimp, were separated for the first time. Although cortical crypts were not present in the periphery of mature oocytes cytoplasm, we observed vesicles accumulated in the cytoplasm of these cells. The histological analysis showed oocytes with synchronous development presenting total spawning. The mean length at maturity (CL₅₀) for females was 1.3 cm CL (cephalothorax length). The reproductive cycle was classified as seasonal for females, with greater ovarian maturity and gonadosomatic index from October to March. The spawning peak occurs during the period of highest rainfall, with a higher percentage of spent females. Our findings suggest that spent females also need to be monitored to establish management measures for the conservation of the species, and not just ripe females, since mature ovaries do not guarantee that they will spawn. These findings may be useful for the sustainable management of commercial penaeid fisheries.

Keywords: histology, ovarian development, reproduction, shrimp fishery.

1. Introduction

The description of the reproductive biology of penaeid shrimp has been an initial objective of many studies that evaluated population development, being essential to identify the reproductive season, size at first maturity and stage of gonadal development (Silva et al., 2016; Peixoto et al., 2018; Craveiro et al., 2019; Garcia et al., 2021). This knowledge can be useful to understand the proper management and conservation measures to prevent overfishing and improve reproductive success of commercially important species (Atherley et al., 2021).

The annual catch of penaeids on the Brazilian coast is around 39,000 tonnes, of which 27% is composed by the Seabob shrimp *Xiphopenaeus kroyeri* (MPA, 2011). Indeed, this species represents an important fishery resource in Brazilian waters and elsewhere, with a high economic, social, and cultural relevance (Gillett, 2008; Silva et al., 2013). The Seabob shrimp is distributed along the western Atlantic coast, from North Carolina, USA, down to Rio Grande do Sul, Brazil (Pérez-Farfante and Kensley, 1997; Costa et al., 2003). Its vertical distribution ranges from 3 to 70 m depth (Pérez-Farfante and Kensley, 1997) and, as opposed to the other penaeid species in the Brazilian coast, it does not use the estuary as a nursery and presents an exclusively marine life cycle (Williams, 1965; Holthuis, 1980).

Although previous studies described the reproductive aspects of the Seabob shrimp caught in Northeast Brazil (e.g., Campos et al., 2009; Reis Jr. et al., 2017; Lopes et al., 2017), they used generalized descriptions from other penaeid species to classify ovarian maturation into four stages, as reported for penaeid species from the Brazilian coast. Furthermore, the separation between the spent and resting ovarian stages has been constantly neglected in studies of penaeid reproduction (Fernandes et al., 2011; Lopes et al., 2014; Grabowski et al., 2014; Fernandes et al., 2014; Castilho et al., 2015; Reis Jr. et al., 2017). To the best of our knowledge, this approach has never been described for Seabob shrimp or any other penaeid species in the world, which allowed us to further refine the reproductive cycle and estimate the spawning season of this species in northeast Brazil.

Hence, the present study describes six ovarian maturation stages for the first time, mean size at sexual maturity, reproductive cycle, and spawning type and season of *X. kroyeri*. This information may support decision making for appropriate management and conservation for penaeids species (Bolognini et al., 2017; Rahman and Ohtomi, 2020), since the success of reproductive biology determines productivity and, therefore,

a population's resilience to fisheries exploitation or other human perturbations (Bolognini et al., 2017).

2. Material and methods

2.1 Sampling and measurements

Specimens of *X. kroyeri* were collected monthly from the artisanal shrimp fishery in Lucena (Figure 1), north coast of Paraíba state ($6^{\circ}53'50''\text{S}$, $34^{\circ}51'01''\text{W}$), from December 2016 to November 2017.

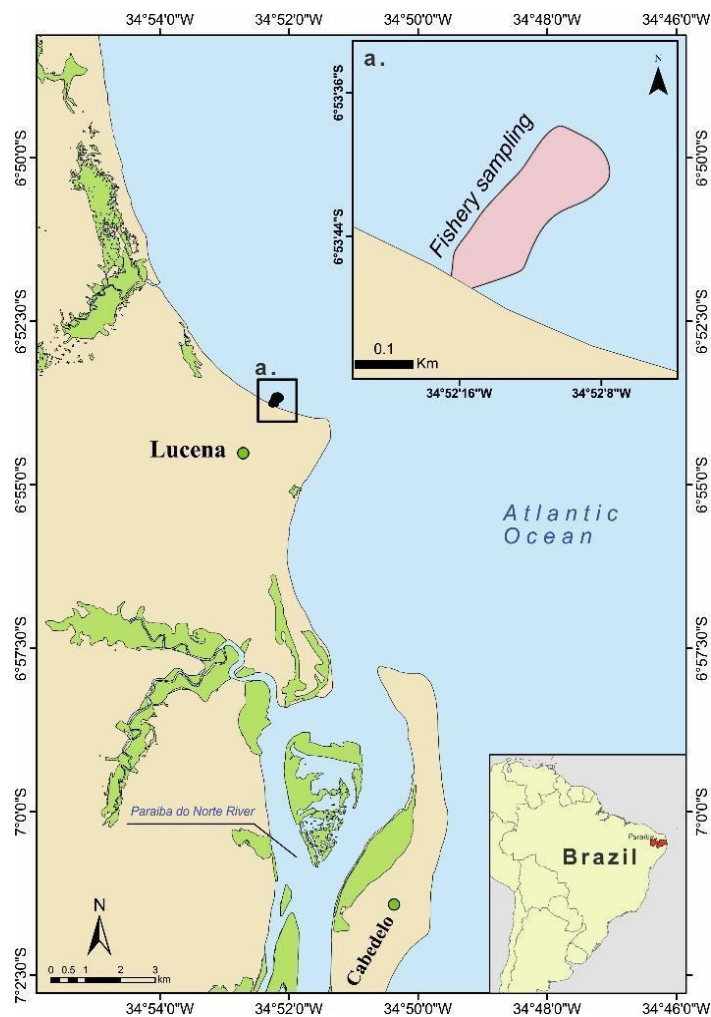


Figure 1. Study area on the north coast of Paraíba State, northeastern Brazil.

Two sets were performed monthly using a beach seine deployed from 500 meters off (depth of 6 meters to the surf zone) and pulled toward the coast, using a non-motorized boat employed by the artisanal fishers. Each set was considered a sampling unit. The shrimps were immediately stored on ice and transported to the laboratory. Temperature ($^{\circ}\text{C}$) and salinity were obtained using a multi-parameter analyzer HANNA

Y (HANNA Y, Limena, Italy). Rainfall and period (dry and rainy season) were based on the local mean precipitation for the last ten years (AESAs).

All specimens were sexed based on external characters (thelycum in females and petasma in males). Total length (TL), cephalothorax length (CL), and the total weight (TW) were recorded using a digital caliper (cm) and precision scale (000.1 g).

2.2 Macroscopic and histological analysis

All sampled females were analyzed macroscopically. The ovary was extracted and its morphology was observed, considering the degree of turgidity and the appearance of the surrounding tissue. The color of the fresh ovary was compared to a widely available chromatic catalogue (Pantone Matching System, Coated Simulation, Pantone, Carlstadt, NJ, USA) to establish a chromatic reference point.

Females were monthly randomly selected and dissected for ovarian histological analysis (n=468). The ovaries were carefully dissected from the dorsal body cavity, and small tissue pieces (5 mm) were taken from the median portion, fixed in saline Davidson's solution for 24 hours and transferred to 70% alcohol for conservation. Sections from the ovary were dehydrated in ascending ethanol series (80, 90%, 95% and 100%), cleared in xylene and embedded in paraffin. Slides were prepared in 5 µm thick sections using a rotary microtome (Leica RM2145, Leica Microsystems, Germany).

Sections were stained with Harris's hematoxylin and counterstained with eosin-phloxine to visualize the gonadal development stage of each sample. Slides were observed under a light microscope (Leica DM500) equipped with a digital camera (Leica ICC50HD). The photomicrographs of the slides were digitized with Leica software with objectives from 4× to 100× of magnification.

2.3 Data analysis

The mean and standard deviation for total weight (TW), total length (TL), and cephalothorax length (CL) by sex were obtained. The population structure has been described considering the for months and sexes differences. Significant differences in CL among them were determined by two-way ANOVA, considering the necessary normality (Kolmogorov–Smirnov test) and homogeneity (Levene test) assumptions.

Tukey's test was performed to verify significant differences from one another between sexes and months in CL (p<0.05). The sex ratio for size classes of 0.1 cm CL was compared using the chi-square test (p<0.05) (Sokal and Rohlf, 1995). The sex ratio

for size classes of 0.1 cm CL was compared using the chi-square test ($p < 0.05$) (Sokal and Rohlf, 1995).

The gonadosomatic index (GSI) was calculated considering only adult females at all stages of gonadal maturation except immature individuals. The following equation was used: $IGS = ((OW/(TW^X)) \times 10^5)$, where OW is the weight of the dissected ovary, TW is the total weight and X is the allometry coefficient (Farrell et al., 2012). The TL, CL, TW, ovary weight, GSI and oocyte diameter (OD) were compared among the different gonad maturation stages using analysis of variance (ANOVA). Tukey's test was then applied to identify the maturation stages that were significantly different ($P < 0.05$) from one another.

The frequency of each phase of oocyte in each development stage was measured in percentage for each field analyzed. Three hundred oocytes per phase, sectioned through the nucleus, were measured from each stage using Leica LAS EZ 3.4 software (Leica Microsystems) to determine the theoretical maximum diameter of each phase of oocyte. Both data were grouped into the different maturation stages based on the most developed oocyte type presence.

The reproductive period was determined based on the proportion of gonad maturation stages per month, classified through the ovary macroscopic and histological analyses. The spawning season was evaluated through the monthly relative frequency of the spent stage. The type of spawning was defined as group-synchronous, two group-synchronous, synchronous in more than two groups or asynchronous, according to the methodology by Wallace and Selman (1981) and Vazzoler (1996) with adaptations.

Size at first sexual maturity was determined for females based on CL, with the estimation of the relative frequency of adults (all females except immature females in each sized class at 0.1 cm intervals). The dispersion between CL and percentage of adult females was adjusted using the nonlinear least-squares iterative method for the determination of CL_{50} using the equation described by King (1995): $P = 1/(1 + \exp[-(a + bCL)])$. The Spearman's rank correlation (r) was performed to measure the associations among the percentage of mature females and temperature, salinity and rainfall at a 5% significance level. The R version 3.3.1 (R Core Team 2016) was used for all statistical analyses ($P < 0.05$).

3. Results

A total of 2,538 shrimp were collected. From those, 1,289 (51%) were females and 1,249 (49%) males, representing a sex ratio statistically similar to 1:1 ($P < 0.05$, Figure 2).

The distribution of absolute frequency per size class for *X. kroyeri* females and males were estimated (Figure 2). Total length ranged from 1.4 to 13.7 cm, in which the females ranged from 2.3 to 13.7 cm (mean \pm SD = 8.1 ± 1.54 cm) and males 1.4 to 13.0 cm (7.72 ± 1.09 cm). Cephalothorax length ranged from 0.62 to 3.3 cm, in which the females ranged from 0.62 to 3.3 cm (1.69 ± 0.37 cm) and males 0.64 - 2.91 cm (1.52 ± 0.25 cm). Total weight ranged from 0.17 to 18.02g, in which the females ranged 0.41–18.02g (3.45 ± 2.05 g) and males 0.17 - 9.94 g (2.66 ± 1.30 g).

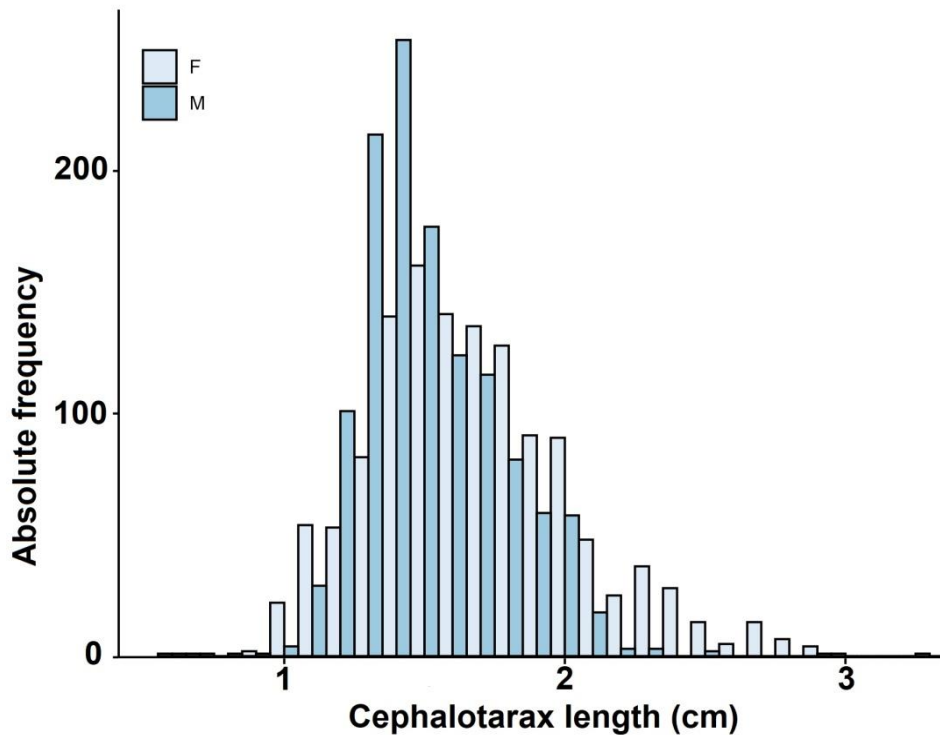


Figure 2. Distribution of absolute frequency per size class (CL – cm) for *X. kroyeri* females (F) and males (M) caught between December 2016 and November 2017 in Lucena, Paraíba state, northeastern Brazil.

3.1 Macroscopic and histological analysis

From the total of 1,289 ovaries analyzed, six distinct maturation stages were determined, based on macroscopic and histological analysis, as follows:

Immature (I): macroscopically, the ovaries were quite small, thin, and present translucent color. Therefore, it was not possible to observe the ovary through the

exoskeleton (Figure 3). The tissue surrounding the ovary was thin, smooth texture and inconsistent. Microscopically, there were a predominance of oogonia (OO) and previtellogenic oocytes (nucleolar chromatin and perinucleolar chromatin - PVTG), measuring $9.35 \pm 2.08 \mu\text{m}$ and $21.37 \pm 10.47 \mu\text{m}$ in diameter, respectively (Figure 4a and b). This stage was observed in 12.10% of the total number of ovaries.

Early developing (II): ovaries were slightly thicker than in immature stage, with greater turgidity in the anterior and lateral lobes located at the middle portion of the cephalothorax. It was possible to observe the ovary through the exoskeleton, as well as its distribution in the cephalothorax due to the light-green color (584 PC, Figure 3). The ovaries can be histologically distinguished by the first appearance of primary vitellogenic oocytes (VTG_1), the most developed oocyte in this stage, measuring $97.51 \pm 5.14 \mu\text{m}$ in diameter, whereas OO and PVTG were also found (Figures 4c and d). This stage was observed in 15.05% of the total number of ovaries.

Advanced developing (III): the anterior and lateral lobes of the ovaries fill the entire cephalothoracic cavity, while the posterior lobes cover part of the abdominal cavity. The colors of ovaries were green (384 PC, Figure 3). As ovaries move into the advanced developing, secondary vitellogenic oocytes (VTG_2) can be observed, being the most developed oocyte in this stage and measuring $135.31 \pm 11.57 \mu\text{m}$ in diameter. Primary vitellogenic oocytes were not observed, but OO and PVTG were also present (Figure 4e and f). This stage was observed in 12.25% of the total number of ovaries.

Ripe (IV): the ripe ovaries fill the entire cephalothoracic and abdominal cavity, presenting a dark green color (575 PC, Figure 3). The histological analysis showed the presence of mature oocytes (MO) showing vesicles in the cytoplasm. These oocytes presented an average diameter of $187.49 \pm 22.18 \mu\text{m}$. In this stage, only MO, OO and PVTG oocytes were observed (Figure 4g and h). This stage was observed in 12.02% of the total number of ovaries.

Spent (V): ovaries were flaccid and had a slightly rough surface with a wrinkled appearance, with color light-green (379 PC). Microscopically, this stage was characterized by the presence of atretic oocytes (AO), which were mature oocytes in the process of reabsorption. It was also possible to observe the presence of postovulatory follicle (POF). The follicular atresia and POF occurs only at this stage. In this stage, only AO, OO and PVTG oocytes were observed (Figure 4i and j). This stage was observed in 9.46% of the total number of ovaries.

Resting (VI): ovaries are flaccid and had a slightly rough surface with a wrinkled appearance, as well as translucent color, which were similar characteristics of the spent stage. The histological analysis showed a thicker cell wall and there were no occurrences of AO and POF. In this stage, only OO and PVTG oocytes were observed (Figure 4k and j). This stage was observed in 39.10% of the total number of ovaries.

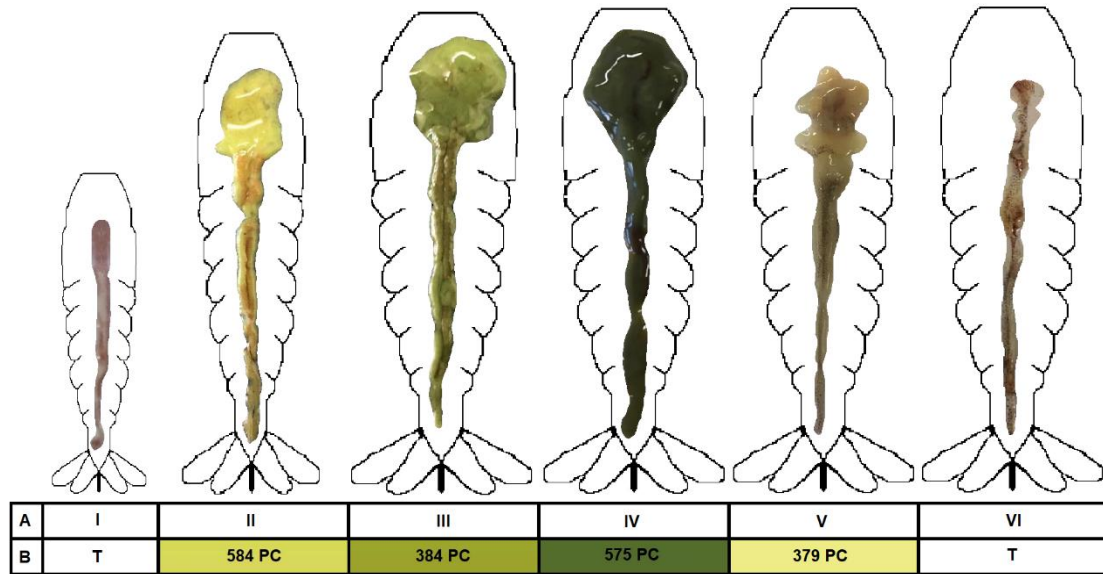


Figure 3. Ovarian maturation stages through macroscopic analysis of the shrimp *X. kroyeri* captured in Lucena, Paraíba, northeastern, Brazil. A) stage of ovarian maturation; B) color of the fresh ovary. I: immature (translucent color; T); II: early developing (584 PC); III: advanced developing (384 PC); IV: ripe (575 PC); V: spent (379 PC); VI: resting (translucent color; T).

Regarding length (TL and CL) and weight (TW) measures, females in stage I were significantly smaller than those in the other ovarian maturation stages. The ovary weight and GSI values increased significantly along the stages II, III and IV, whereas no significant difference was found among stages I, V and VI which presented lower GSI (Table 1). The mean GSI values increased sequentially from 0.20 ± 0.09 when immature to a maximum of 6.48 ± 4.06 when ripe, followed by a sharp decrease at spent to 0.91 ± 0.43 and resting to 0.69 ± 0.35 (Table 1).

Table 1. Mean (\pm SD) total length (TL), cephalothorax length (CL), total weight (TW), ovary weight (OW) and gonadosomatic index (GSI) in six ovarian maturation stages of *X. kroyeri* females in Lucena, Paraíba, northeastern Brazil.

	I	II	III	IV	V	VI
	(n=156)	(n=194)	(n=158)	(n=155)	(n=122)	(n=504)
TL (cm)	5.73 \pm 0.92 ^a	8.74 \pm 1.30 ^b	8.88 \pm 1.35 ^b	9.05 \pm 1.18 ^b	8.28 \pm 1.13 ^b	8.91 \pm 1.09 ^b
CL (cm)	1.15 \pm 0.11 ^a	1.82 \pm 0.36 ^b	1.85 \pm 0.38 ^b	1.86 \pm 0.30 ^b	1.70 \pm 0.30 ^b	1.82 \pm 0.27 ^b
TW (g)	1.25 \pm 0.48 ^a	4.03 \pm 2.09 ^b	4.35 \pm 2.33 ^b	4.64 \pm 2.24 ^b	4.29 \pm 1.67 ^b	4.38 \pm 1.37 ^b
OW (g)	0.02 \pm 0.01 ^a	0.08 \pm 0.11 ^b	0.23 \pm 0.12 ^c	0.48 \pm 0.29 ^d	0.03 \pm 0.01 ^a	0.02 \pm 0.01 ^a
GSI (%)	0.20 \pm 0.09 ^a	1.53 \pm 0.81 ^b	3.64 \pm 3.15 ^c	6.48 \pm 4.06 ^d	0.91 \pm 0.43 ^a	0.69 \pm 0.35 ^a

* Values in the same line with different letters are significantly different ($P < 0.05$).

** n = Total sample number.

The histological analysis showed OO and PVTG in all ovarian development stages, with higher frequencies in the immature, spent and resting stages (Table 2). These oocytes showed a similar diameter throughout the ovarian development stages, but PTVG showed a significantly lower diameter in immature compared to other stages. During ovarian maturation, an increase in the cytoplasm area was observed and vitellogenic oocytes emerged (VTG₁ and VTG₂) during developing stages (early and advanced), followed by MO in the ripe stage. The diameter of the five phases of oocytes measured was significantly different among each other (Table 2).

The cell phases differed among ovarian developmental stages, except between immature and resting (Table 2). The immature stage was histologically distinguished from the resting stage by the significantly smaller size of the OO and PVTG (Table 2), lack of space among oocytes, and larger amount of connective tissue present in the resting ovary. The presence of postovulatory follicles complex and follicular atresia occurred only in the spent stage (Figure 4j). All other ovarian maturation stages presented distinct oocytes with specific characteristics attributed to the respective stage (Table 2; Figure 4).

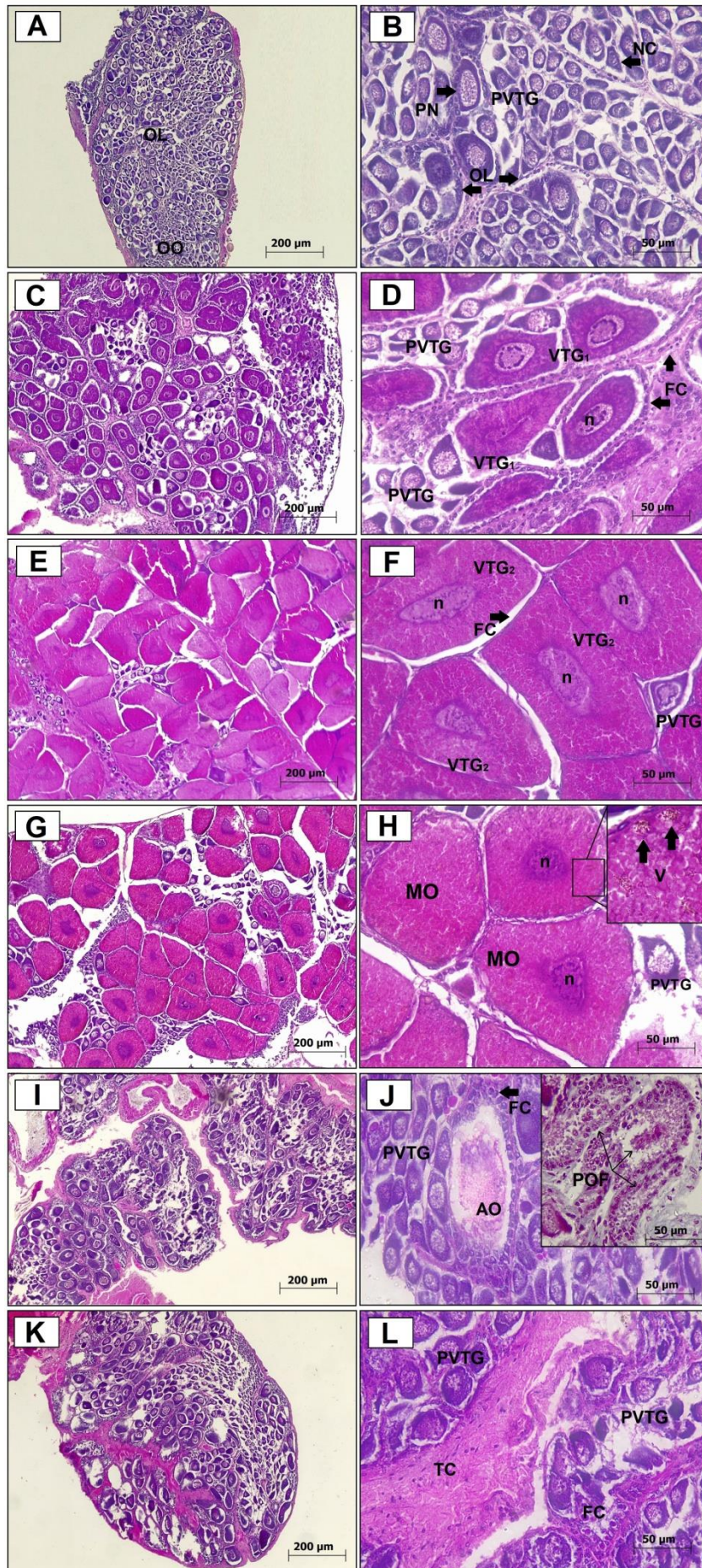


Figure 4. Photomicrographs of ovarian maturation in *X. kroyeri*: A-B) immature stage, showing previtellogenic oocytes (PVTG); C-D) early maturing stage, with primary vitellogenic oocytes (VTG₁); E-F) advanced maturing stage, with secondary vitellogenic oocytes (VTG₂); G-H) ripe stage, showing mature oocytes (MO) with vesicles (V) in the cytoplasm; I-J) spent stage, showing atretic oocytes (AO) and postovulatory follicle (POF); K-L) resting stage, with previtellogenic oocytes and flaccid tissue connective (TC). OO: oogonia; NC: nucleolar chromatin; PN: perinucleolar chromatin; ol: ovigerous lots; n: nucleus; FC: follicular cells. Scale bars: figures in left side 200 µm, right side 50 µm, and highlight figures 20 µm (H and J).

Table 2. Frequency and diameter (mean ± SD) for each oocyte phase observed in each stage (I - VI) of gonadal maturity of *X. kroyeri*. Oogonia (OO), previtellogenic oocytes (PVTG), primary vitellogenic oocytes (VTG₁), secondary vitellogenic oocytes (VTG₂), mature oocytes (MO) and Atretic oocytes (AO). I) Immature; II) Early developing; III) Advanced developing; IV) Ripe; V) Spent; VI) Resting. (-): not present.

Stage	Frequency of oocyte phase in the ovaries (%)					
	OO	PVTG	VTG ₁	VTG ₂	MO	AO
I	79.84±5.63 ^a	20.16±2.35 ^a	-	-	-	-
II	52.13±4.21 ^b	17.78±3.74 ^a	30.09±4.81 ^c	-	-	-
III	58.63±5.74 ^b	16.31±2.89 ^a	-	25.06±6.14 ^d	-	-
IV	53.31±7.69 ^b	19.12±3.76 ^a	-	-	27.57±5.74 ^e	-
V	73.14±6.47 ^a	22.71±5.14 ^a	-	-	-	4.15±1.08 ^f
VI	67.78±4.21 ^a	32.22±3.85 ^b	-	-	-	-

Stage	Diameter of oocyte phase in the ovaries (µm)					
	OO	PVTG	VTG ₁	VTG ₂	MO	AO
I	9.35±2.08 ^a	21.37±10.47 ^a	-	-	-	-
II	9.72±1.88 ^a	45.69±11.13 ^b	97.51±5.14 ^c	-	-	-
III	10.05±2.12 ^a	42.19±8.20 ^b	-	135.31±11.57 ^d	-	-
IV	10.18±1.98 ^a	39.41±15.12 ^b	-	-	187.49±22.18 ^e	-
V	9.92±2.04 ^a	44.18±22.14 ^b	-	-	-	-
VI	9.71±2.31 ^a	45.78±18.14 ^b	-	-	-	-

* Values in the same line and column with different letters are significantly different (p < 0.05).

3.2 Spawning type and size at maturity

Histological analyses showed a constant presence of reserve oocytes (OO and PVTG) in all ovarian development stages (Figure 5). Although gonadal maturation of females occurred in ovigerous lots, the oocyte size progression occurred with

development of only one cell group reaching the mature oocyte stage, while maintaining reserve oocytes (Figure 5). The development of a single oocyte class group during the maturation process indicates a total spawning with a group-synchronous (Figure 5). The mean length at first maturity (CL₅₀) for females was 1.3 cm CL (Figure 6).

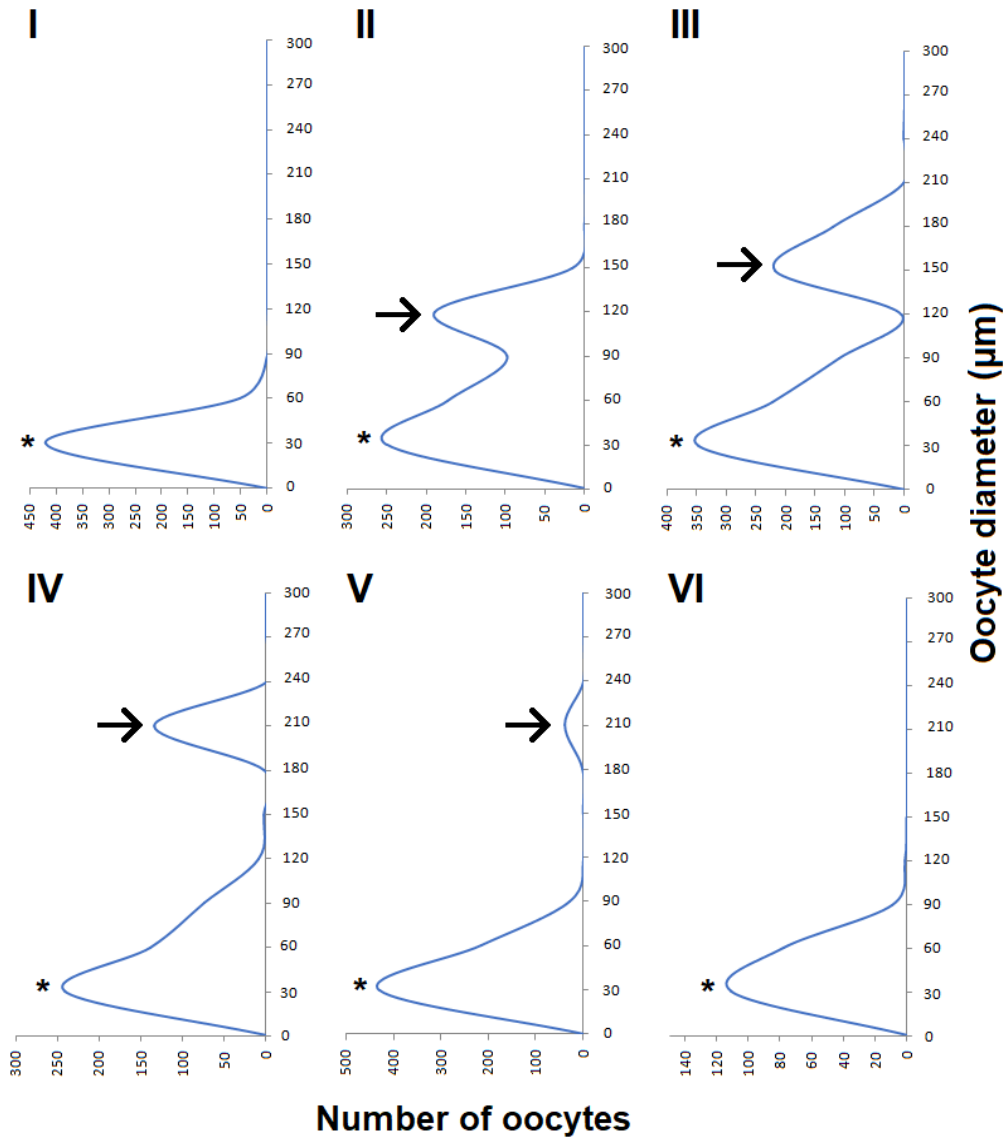


Figure 5. Frequency distribution of the oocyte diameter in each phase, in the six ovarian maturation stages of *X. kroyeri* caught in Lucena-PB, northeastern Brazil, between December/2016 to November/2017. I) immature; II) early maturing; III) advanced maturing; IV) ripe; V) spent; VI) resting. Black arrows indicate the most developed oocyte group, while asterisks represent reserve oocytes.

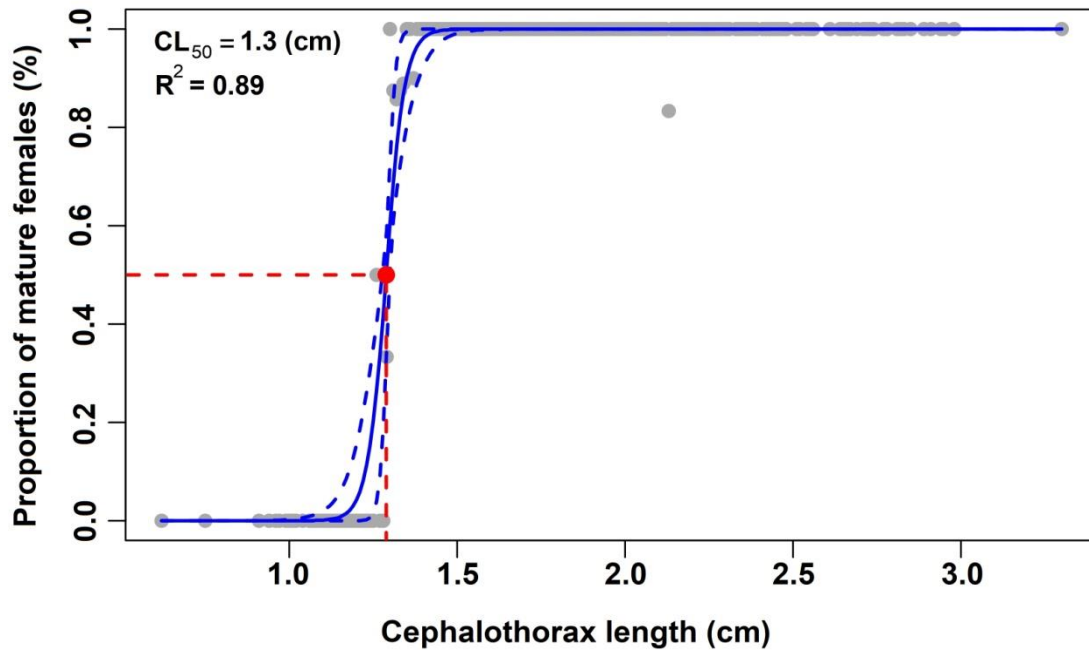


Figure 6. Length (cephalothorax, CL) at maturity of *X. kroyeri* females caught between December 2016 and November 2017 in Lucena, Paraíba, northeastern Brazil.

3.3 Physicochemical variables and reproductive cycle

The water temperature ranged from 26.3 to 30.6°C, while salinity varied from 37.3 to 42.5. Both temperature and salinity were higher in October and January. The rainy season was considered between March and August (144.21– 322.56 mm) and dry season between September and February (< 109.02 mm). Spearman's rank correlation revealed significant associations among the percentage of mature females and salinity (p-value = 0.0046; $r = 0.7535$; $P < 0.05$), rainfall (p-value = 0.0053; $r = -0.7465$; $P < 0.05$) and temperature (p-value = 0.0019; $r = 0.6620$; $P < 0.05$). The highest percentage of ripe and spent females was observed in dry season and females resting were observed from June to October, in the rainy season (Figure 7).

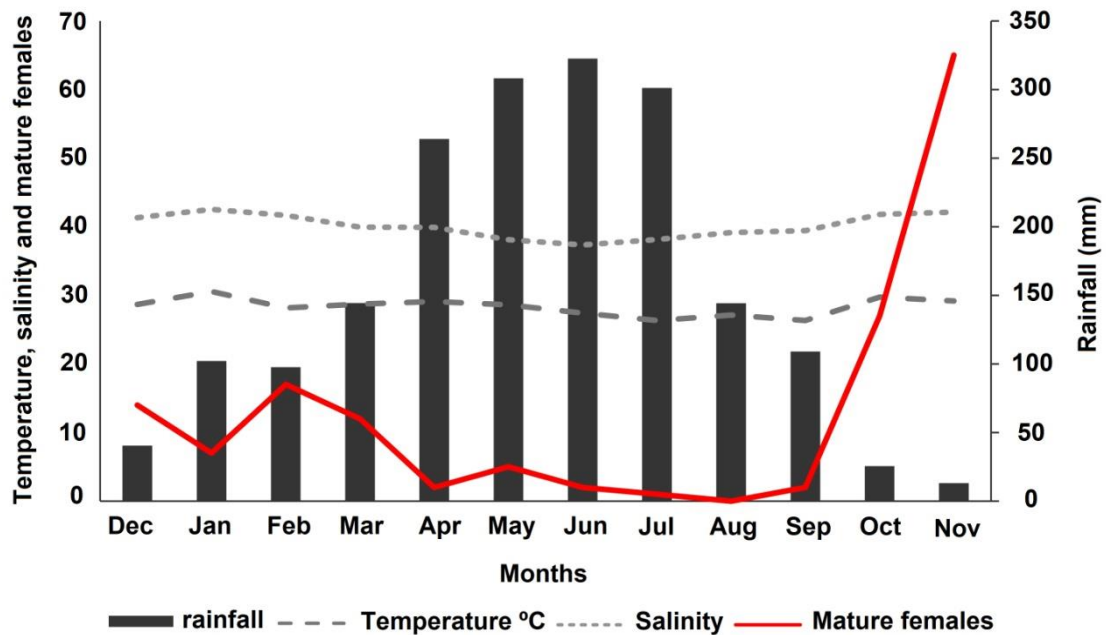


Figure 7. Physicochemical variables (salinity and temperature), mean rainfall (last 10 years) and number of mature *X. kroyeri* females caught between December 2016 and November 2017 in Lucena, Paraíba, northeastern Brazil.

The mean gonadosomatic index (GSI) per month showed a seasonal trend throughout the year, with a progressive increase starting from October and peaking in January (7.04%), due to the higher presence of mature females in these months. In contrast, a sharp decrease was observed in February towards its lowest value in July (0.95%), which were the months that presented more spent females and resting females, respectively (Figure 8). This sharp drop of GSI in February probably represents the beginning of spawning.

The reproductive cycle of females may be classified as seasonal, with greater gonadal maturation (higher percentage of ripe females) from October to March (dry season). Spent females showing postovulatory follicle and atretic oocytes were observed in April and May, indicating intense spawning activity in these months. From June to September was observed the highest occurrence of resting females, with only two ripe females sampled (one per month). The highest relative occurrence of immature individuals was found in May, which was right after the reproductive period (Figure 8).

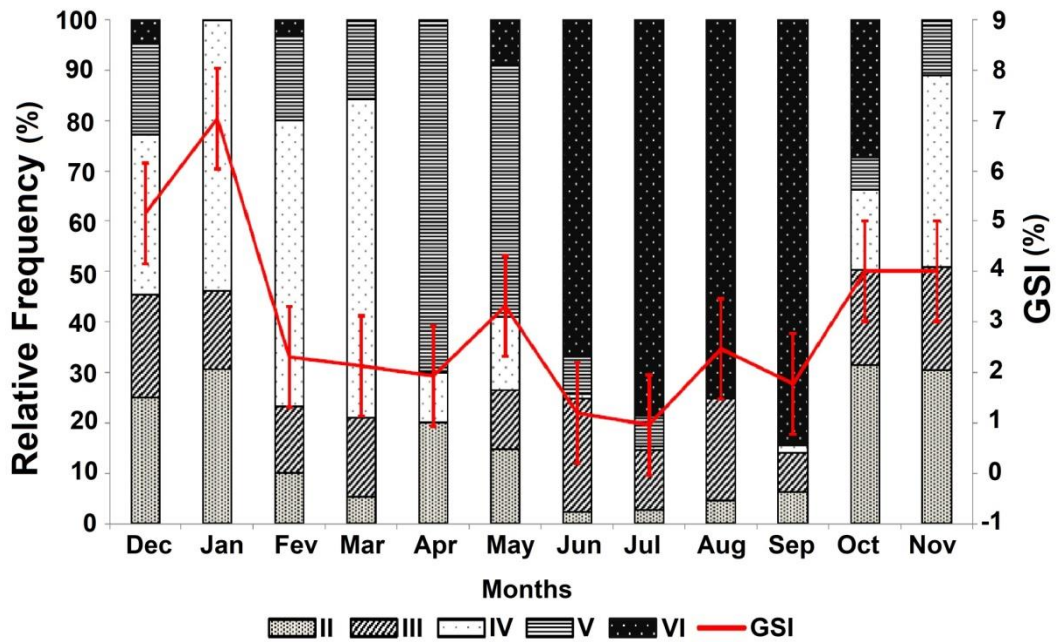


Figure 8. Relative frequency of ovarian development stages of *X. kroyeri* females caught between December 2016 and November 2017 in Lucena, Paraíba, northeastern Brazil. II: early maturing; III: advanced maturing; IV: ripe; V: spent; VI: resting. GSI: monthly mean and standard deviation of gonadosomatic index (%).

4. Discussion

Although the predominance of females over males was observed in several studies of penaeids including *Penaeus kerathurus* (Bolognini et al., 2017), *Penaeus schmitti* (Craveiro et al., 2019), *Artemesia longinaris* (Costa et al., 2010) and *X. kroyeri* (Lopes et al., 2017), no significant differences were found between the abundance of males and females in the present study. According to Wenner (1972), differences in the life cycle, migration, mortality, growth rates, and behavior between males and females may be related to the balance in the sex ratio, resulting in deviations from the expected 1:1 sex ratio for gonochoristic species. Other factors such as fishing and temperature may also be relevant (Tu et al., 2018).

Females were larger and heavier than males in our study, which seems to be a common characteristic of penaeids (Fernandes et al., 2011; Sancinetti et al., 2015). Some authors proposed that females have larger cephalothorax and abdomen due to reproductive activities, since a large body is required for ovarian development (Hartnoll, 1982; Dall et al., 1990; Gab-Alla et al., 1990).

The ovarian classification based on macroscopic characteristics closely matched with histological analysis of *X. kroyeri*. Several studies reported problems mainly in macroscopically differentiating spent from immature ovaries through the shrimp carapace (Silva et al., 2016; Lopes et al., 2017; Craveiro et al., 2019). In the present study all stages showed different colors and morphology, but even though immature (I) and resting (VI) stages were similar in color (translucent), they were different in weight and appearance. Thus, we consider essential to extract the ovaries for a more reliable macroscopic evaluation to distinguish between these stages, since only observations through the carapace have been used in several studies of penaeid reproductive dynamics (e. g. Castilhos et al., 2015; Reis Jr. et al., 2017).

During ovarian development, changes were observed in oocytes size and histological characteristics, which were consistent with other studies of penaeids (Yano, 1988; Ohtomi and Yamamoto, 1997; Silva et al., 2016; Lopes et al., 2017). It was also observed that there is a proliferation zone in which oogonia are concentrated (Peixoto et al., 2018; Craveiro et al., 2019). Oogonia and previtellogenic oocytes were found predominantly in the immature, spent and resting stages, but it is possible to find them in all maturation stages. The presence of oogonia and previtellogenic oocytes in all stages of gonadal development suggests their role as reserve oocytes, indicating that *X. kroyeri* spawning more than once during its life cycle.

As *X. kroyeri* ovarian development progressed, the cytoplasm increased and vitellogenic oocytes emerged (VTG₁ and VTG₂), followed by ripe oocytes. In a previous study with this species in another region of northeast Brazil, Lopes et al. (2017) reported only one type of vitellogenic oocyte. In contrast, we described for the first time two different types of vitellogenic oocytes, showing different histological characteristics and diameter for *X. kroyeri*. The rapid increase in oocyte diameter and size found in our study is probably caused by yolk accumulation, specifically because of vitellogenin, which accumulates in oocytes as an important yolk protein during vitellogenesis to serve as a source of nutrients (minerals, lipids, and other materials) for oocyte development (Wilder et al., 2010).

The mature oocytes of *X. kroyeri* did not present cortical cripts, which is a major difference from the final maturation stage of several penaeid species (Ayub and Ahmed, 2002; Silva et al., 2016; Bolognini et al., 2017; Peixoto et al., 2018; Craveiro et al., 2019; Garcia et al., 2021). This fact led us to believe that the development of visible cortical cripts might not be a prerequisite to attain final maturation and spawning in all

the penaeid species, as also suggested for *Metapenaeopsis dalei* (Sakaji et al., 2000), *Metapenaeopsis monoceros* (Abraham and Manisseri, 2012), *Penaeus indicus* (Henry et al., 2019), *Metapenaeopsis sibogae* and *Metapenaeopsis provocatoria owstoni* (Rahman and Ohtomi, 2017; 2020). Although Lopes et al. (2017) have mentioned cortical cripts-like structures for *X. kroyeri* in northeast Brazil, these authors did not detail the photomicrographs of these structures in their study. In the present study, we observed vesicles accumulated in the cytoplasm of the mature oocytes. However, we believe that their chemical constitution is not similar, since they are filled with granular material and react differently to hematoxylin-eosin (Figure 4H - black arrow), which differs markedly from what has been shown by other authors using a similar staining method (Peixoto et al., 2003; Silva et al., 2016; Peixoto et al., 2018; Craveiro et al., 2019). We suggest that these vesicles have the same function as the cortical cripts in other penaeid oocytes, which is assisting in the release of a gelatinous substance around the oocyte to promote sperm fixation and formation of the hatching envelope (Clark jr. et al., 1980; Yano, 1988). Nonetheless, the vesicles in ripe oocytes of the *X. kroyeri* should be further studied at the histochemical and ultrastructural level to elucidate this hypothesis.

The fact that VTG₁, VTG₂ and ripe oocytes were not found in the same gonad of *X. kroyeri* indicates synchrony in oocyte development. This is rather unusual since several studies have reported asynchronous development of oocytes in penaeids, such as *Penaeus latisulcatus* (Penn, 1980), *Penaeus merguensis* (Crococ and Kerr, 1983), *M. dalei* (Sakaji et al., 2000), *Metapenaeopsis aegyptia*, *M. barbata*, and *Metapenaeopsis sinica* (Sakaji, 2001), *Metapenaeopsis palmensis* (Chen et al., 2014) and *Metapenaeopsis sibogae* (Rahman and Ohtomi, 2017). Although it is uncommon, Craveiro et al. (2019) observed synchronous development in *P. schmitti* oocytes in the same region. The authors raised the hypothesis that environmental conditions would be responsible for this behaviour of *P. schmitti*, as high temperatures and salinity were recorded throughout the year in the area, favoring the faster development of oocytes.

Although Lopes et al. (2017) and Reis Jr. et al. (2017) reported four ovarian maturation stages of *X. kroyeri* (immature, maturing, mature and spawned), we have observed six stages based on macroscopic and histological analysis. These authors did not find the resting stage, confirmed here by the absence of atretic oocytes and postovulatory follicle, which were presented only in the spent stage. Also, they did not separate early maturing (II) and advanced maturing stages (III), confirmed in the present study by the accumulation of yolk in these oocytes and differences between their

diameters. Although these stages II and III are not histologically similar, they do not result in misinterpretation of penaeid reproductive season when grouped in a single stage. However, merging spent and resting stages into one stage is a major problem, since they present opposite characteristics and interpretations of the reproductive cycle. While the spent stage means intense reproductive activity due to the recent spawning, the resting stage implies the absence of any type of reproductive activity. In other words, combining both stages may lead to serious problems in estimating the spawning season, which is common in studies of reproduction of penaeid shrimps.

The management of commercially exploited fisheries requires information on the size at the first maturity of the target species, which should be regularly re-evaluated (Watters and Hobday, 1998; Öndes et al., 2017). In this regard, we estimated the average first maturity length for *X. kroyeri* females at 1.3 cm CL. Lopes et al. (2014) reported 1.95 cm and Reis Jr. et al. (2017) 1.58 cm in northeastern Brazil, while Castilho et al. (2015) estimated 1.24 cm in the southeast coastal population of *X. kroyeri*. Although these values are within a similar range, small variations in the mean size at first maturity may be related to fishing effort, environmental factors such as increasing seawater temperatures and changes in food availability, which may lead to an anticipation of the gonadal maturity of individuals (Landers et al., 2001; Linnane et al., 2008; Tu et al., 2018). Moreover, Dall et al. (1990) suggested that mean size at first maturity depended on physicochemical variables, seasons, variation in depth and latitude.

Considering the GSI values, as well as the macroscopic and microscopic ovarian analysis, we suggested that the reproduction cycle is classified as seasonal for *X. kroyeri*, with a higher percentage of mature females from October to March (dry season). Reis jr et al. (2017) reported that the reproductive period was continuous for *X. kroyeri* as females in mature and spent stages were found throughout the year, with a reproductive peak in August-September in Sergipe, northeast of Brazil. Possibly, the lack of agreement at the peak of reproduction with our study occurred because these authors merging spent and resting stages into one stage; and only macroscopic analysis was used to estimate the stages of gonadal maturation. Likewise, a recent study in northeast of Brazil suggested two seasonal peaks in November/December and February for *X. kroyeri* using histological analysis (Lopes et al., 2017), although these authors also grouped the spent and resting stages, leading to different interpretations. Furthermore, observations of the reproductive cycle along with the spawning type

indicate that this species spends a period of time in spawning recovery (resting phase) before starting a new maturation cycle. This fact suggests that different females were spawning from October to March since this time interval was probably not enough for ovarian rematuration, which was indicated by the lacking of new ovigerous lots after spawning.

The reproductive aspects of penaeids are directly associated with temperature, salinity, and food availability (Crocós and Van Der Velde, 1995; Aragón-Noriega and Alcántara-Razo, 2005; Kevrekidis and Thessalou-Legaki, 2013). The salinity, temperature and rainfall showed a significant correlation with the reproductive cycle of *X. kroyeri* in the present study. We observed that the spawning occurs during rainy season probably due to the increased abundance of food, which could favor recruitment, since high rainfall leads to the enrichment of nutrients in the habitat, creating favorable conditions for the growth and development of the initial larval stages (Dato-On-Subong and del Norte-Campos, 2015; Paschoal., 2016). Although the salinity at the study area was very high throughout the year, the intensification of rainfall was directly related to the reductions in salinity (42.52 to 37.34, in summer and winter, respectively) and the number of mature individuals during this period. Young et al. (2018) and Craveiro et al. (2019) proposed that salinity is an important factor influencing the reproduction of *Metapenaeus bennettiae* in New South Wales, Australia and *P. schmitti* in northeastern, Brazil, respectively. Nevertheless, between June and September, the number of females at the resting stage increased and there were no mature and spent females in this period, indicating a period in which the females recover until the next reproductive season.

During the study period, water temperature was relatively constant and never dropped below 26.3°C. However, in January and October the temperature reached the highest values (30.5°C and 29.7 °C, respectively), which was coincident with the highest number of *X. kroyeri* mature females in the area, resulting in the period of greatest gonadal maturation. Indeed, the temperature is an important stimulus which influences physiological factors such as reproduction (FAO/WECAFC, 2018; Sastry, 1983; Bauer, 1992), and even a small increase in mean its values as observed in our study (3 to 4°C) may affect the reproductive cycle of penaeids. Finally, in future management plans aimed at the conservation of penaeid shrimp, we suggest that spent as well as ripe females should also be monitored, since attaining final ovarian maturation does not guarantee that they will spawn. In regions where environmental

variables exhibit large variation throughout the year, monitoring spent females will possibly ensure more effective management.

In summary, we observed that females of *X. kroyeri* present six stages of ovarian development based on macroscopic and histological features: immature, early developing, advanced developing, ripe, spent and resting. Cortical cripts in the cytoplasm periphery of ripe oocytes were not identifiable in Seabob shrimp, which is unusual for penaeids. Instead, we observed vesicles in the cytoplasm of the mature oocytes, suggesting that they perform a similar function. The salinity, temperature, and rainfall showed a significant correlation with the reproductive cycle of females, which was considered seasonal, with a higher percentage of ripe females from October to March (dry season). The most intense spawning season occurs during the period of highest rainfall, with a higher percentage of spent females. The observation of the environmental variables, ovarian development stages, and spawning season leads us to suggest that spent as well as mature females should be monitored to establish management measures. The information contained here may be useful for the sustainable management of commercial penaeids fisheries.

Funding

This study is a contribution of the projects "Shrimp NE_N" (Grant Number: 445766/2015-8), which has received funding from the Secretaria da Pesca e Aquicultura (MAPA/SAP), Brazil and Conselho Nacional de Desenvolvimento Científico e Tecnológico (CNPq), Brazil and of "Subsídios para o manejo sustentável da pesca de camarões no litoral norte da Paraíba", also financed by CNPq, Brazil. Cecília Craveiro is supported by Coordenação de Aperfeiçoamento de Pessoal de Nível Superior (CAPES). Silvio Peixoto and Flávia Lucena Frédou are supported by a research grant of CNPq, Brazil.

References

- Abraham J., Manisseri M.K., 2012. Histological and morphological changes associated with ovarian development of speckled shrimp *Metapenaeus monóceros* (Fabricius, 1798). Indian J. Fish. 59 (1), 119–124. <http://eprints.cmfri.org.in/id/eprint/8933>
- AESA. Agência Executiva de Gestão das Águas. <http://www.aesa.pb.gov.br> (Accessed 15 July 2020).

Aragón-Noriega E.E., Alcántara-Razo E., 2005. Influence of sea surface temperature on reproductive period and size at maturity of brown shrimp (*Farfantepenaeus californiensis*) in the Gulf of California. *Mar Biol.* 146, 373–379. <https://doi.org/10.1007/s00227-004-1442-3>

Atherley N.A.M., Dennis M.M., Behringer D.C., Freeman M.A., 2021. Size at sexual maturity and seasonal reproductive activity of the Caribbean spiny lobster *Panulirus argus*. *Mar EcolProg Ser.* 671, 129–145. <https://doi.org/10.3354/meps13762>

Ayub Z., Ahmed M.A., 2002. Description of the ovarian development stages of penaeid shrimp from the coast of Pakistan. *Aquacult Res.* 33, 767–776. <https://doi.org/10.1046/J.1365-2109.2002.00715.X>

Bauer R.T., 1992. Testing generalizations about latitudinal variation in reproduction and recruitment patterns with sicyoniid and caridean shrimp species. *Invertebr. Reprod. Dev.* 22, 193–202. <https://doi.org/10.1080/07924259.1992.9672272>

Bolognini L., Donato F., Lucchetti A., Olivotto I., Truzzi C., Randazzo B., Antonucci M., Illuminati S., Grati F., 2017. A multidisciplinary approach to study the reproductive biology of wild prawns. *Sci. Rep.* 7(1), 16781. <https://doi.org/10.1038/s41598-017-16894-1>

Campos B.R., Dumont L.F.C., D’Incao F., Branco J.O., 2009. Ovarian development and length at first maturity of the sea bob shrimp *Xiphopenaeus kroyeri* (Heller) based on histological analysis. *Nauplius.* 17, 9–12. https://crustacea.org.br/wp-content/uploads/2014/02/nauplius-v17n1a02.Campos.et_al_.pdf

Castilho A.L., Bauer R.T., Freire F.A.M., Fransozo V., Costa R.C., Grabowski R.C., Fransozo A., 2015. Lifespan and reproductive dynamics of the commercially important sea bob shrimp *Xiphopenaeus kroyeri* (Penaeoidea): synthesis of a 5-year study. *J. Crustac. Biol.* 35, 30–40. <https://doi.org/10.1163/1937240X-00002300>

Chen H.S., Chen C.Y., Chen M.H., 2014. Life history tactics of southern velvet shrimp *Metapenaeopsis palmensis* (Crustacea, Decapoda) in the waters off southwestern Taiwan. *Hydrobiologia.* 741, 177–191. <https://doi.org/10.1007/s10750-014-1830-8>

Clark-Jr W.H., Lynn J.W., Persyo H.O., 1980. Morphology of the cortical reaction in the eggs of *Penaeus aztecus*. *Biol. Bull.* 158(2), 175–186. <https://doi.org/10.2307/1540929>

Costa R.C., Fransozo A., Melo G.A.S., Freire F.A.M., 2003. Chave ilustrada para identificação dos camarões Dendrobranchiata do litoral norte do estado de São Paulo, Brasil. *Biota Neotrop.* 3, 1–12. <http://doi.org/10.1590/S1676-06032003000100011>

Costa R.C., Branco J.O., Machado I.F., Campos B.R., Ávila M.G., 2010. Population biology of shrimp *Artemesia longinaris* (Crustacea: Decapoda: Penaeidae) from the southern coast of Brazil. *J. Mar. Biolog. Assoc. U.K.* 90, 663–669. <https://doi.org/10.1017/S002531540999124X>

Craveiro C., Peixoto S., Silva E.F., Eduardo L.N., Lira A.S., Castro-Neto H., Frédou F.L., Soares R., 2019. Reproductive dynamics of the white shrimp *Litopenaeus schmitti* (Burkenroad 1936) in a beach seine fishery in northeastern Brazil, *Invertebr.Reprod. Dev.* 1–11. <https://doi.org/10.1080/07924259.2019.1575923>

Crococ P.J., Kerr J.D., 1983. Maturation and spawning of the banana prawn *Penaeus merguensis* de Man (Crustacea: Penaeidae) in the Gulf of Carpentaria, *Austr. J. Exp. Mar. Biol. Ecol.* 69, 37–59. [https://doi.org/10.1016/0022-0981\(83\)90171-5](https://doi.org/10.1016/0022-0981(83)90171-5)

Crococ P.J., Van Der Velde T.D., 1995. Seasonal, spatial and interannual variability in the reproductive dynamics of the grooved tiger prawn *Penaeus semisulcatus* in Albatross Bay, Gulf of Carpentaria, Australia: the concept of effective spawning. *Mar Biol.* 122(4), 557–570. [https://doi.org/10.1016/S0044-8486\(97\)00109-9](https://doi.org/10.1016/S0044-8486(97)00109-9)

Dall W., Hill B.J., Rothlisberg P.C., Staples D.J., 1990. The biology of the penaeidae. *Advances in marine biology.* London: Academic Express.

Dato-On-Subong K., Del Norte-Campos A.G.C., 2015 Reproductive biology of the Sulu shrimp *Metapenaeus suluensis* Racek and Dall 1965 (Crustacea, Malacostraca: Penaeidae) in Iloilo River, west central Philippines. *Asian Fish. Sci.* 28, 89-101. <https://doi.org/10.33997/j.afs.2015.28.3.001>

FAO/WECAFC, 2018. The regional Caribbean spiny lobster (*Panulirusargus*) fishery management plan. Ninth Session of the Scientific Advisory Group.WECAFC/SAG/IX/2018/6. FAO, Rome.

Farrell E.D., Hussy K., Coad J.O., Clausen L.W., Clarke M.W., 2012. Oocyte development and maturity classification of boarfish (*Capros aper*) in the Northeast Atlantic. *ICES, Int. J. Mar. Sci.* 69(4), 498–507. <https://doi.org/10.1093/icesjms/fss037>

Fernandes L.P., Keunecke K.A., Di Benedetto A.P.M., 2014. Analysis of mortality and exploitation of a stock of shrimp *Xiphopenaeus kroyeri* in the Southwestern Atlantic Ocean. *Int. j. fish. aquat.* 2, 57–63. <https://www.fisheriesjournal.com/vol2issue1/Pdf/19.1.pdf>

Fernandes L.P., Silva A.C., Jardim L.P., Keunecke K.A., Di Benedetto A.P.M., 2011. Growth and recruitment of the Atlantic Seabob shrimp, *Xiphopenaeus kroyeri* (Heller, 1862) (Decapoda, Penaeidae), on the coast of Rio de Janeiro, southeastern Brazil. *Crustaceana*. 84, 1465–1480. <https://doi.org/10.1163/156854011X605765>

Gab-Alla A.A.F.A., Hartnoll R.G., Ghobashy A.F., Mohammed S.Z., 1990. Biology of penaeid prawns in the Suez Canal lakes. *Mar Biol.* 107, 417–426. <https://link.springer.com/article/10.1007/BF01313423>

Gillett R., 2008. Global study of shrimp fisheries. FAO Fisheries Technical Paper. N° 475. Rome, FAO. 2008. 331p. <http://www.fao.org/3/i0300e/i0300e.pdf>

Garcia R.C.P., Craveiro, C.F.F., Bernabé C.V., Silva M.A., Aride P.H.R., Oliveira A.T., Gonçalves F.R.S.C., Santander-Neto J., Lavander H.D., Faggio C., 2021. Gonadal development of females of the white shrimp *Penaeus schmitti* (Burkenroad, 1936) caught in southeastern Brazil. *J. Mar. Sci. Eng.* 29, 653. <https://doi.org/10.3390/jmse9060653>

Grabowski R.C., Simões S.M., Castilho A.L., 2014. Population structure, sex ratio and growth of the Seabob shrimp *Xiphopenaeus kroyeri* (Decapoda, Penaeidae) from coastal waters of southern Brazil. *Zookeys*. 457, 253–269. <https://doi.org/10.3897/zookeys.457.6682>

Hartnoll R.G., 1982. Growth. In: Abele LG (ed) *The biology of Crustacea*, Vol 2: embryology, morphology, and genetics. Academic Press, New York, NY, p 111–196.

Henry C.B., Mulanda C.A., Njiru J., 2019. Ovarian Development of the Penaeid Shrimp *Penaeus Indicus* (Decapoda): A Case for the Indian Ocean Coastal Waters of Kilifi Creek, Kenya. *Fish Aqua J.* 10, 262. <https://doi.org/10.4172/2150-3508.1000262>

Holthuis L.B., 1980. Shrimp and prawns of the world. An annotated catalogue of species of interest to fisheries. FAO Species Catalogue, Roma, 1: 1-261. <http://www.fao.org/3/ac477e/ac477e.pdf>

Kevrekidis K., Thessalou-Legaki M., 2013. Reproductive biology of the prawn *Melicertus kerathurus* (Decapoda: Penaeidae) in Thermaikos Gulf (N. Aegean Sea). *Helgol Mar Res.* 67, 17–31. <https://doi.org/10.1007/s10152-012-0301-8>

King M., 1995. Fisheries biology, assessment and management. London (UK): Fishing News Books, Oxford Press, 341 p.

Landers D.F., Keser M., Saila S.B., 2001. Changes in female lobster (*Homarus americanus*) size at maturity and implications for the lobster resource in Long Island Sound, Connecticut. *Mar Freshw Res.* 52, 1283–1290. <https://doi.org/10.1071/MF01045>

Linnane A.J., Penny S.S., Ward T.M., 2008. Contrasting fecundity, size at maturity and reproductive potential of southern rock lobster *Jasus edwardsii* in two South Australian fishing regions. *J Mar Biol.* 88, 583–589. <https://doi.org/10.1017/S0025315408001021>

Lopes D., Frédou F.L., Silva E., Calazans N., Peixoto S., 2017. Reproductive cycle of Seabob shrimp *Xiphopenaeus kroyeri* (Crustacea, Penaeidea) from the northeast coast of Brazil. *Invertebr. Reprod. Dev.* 61,1-5. <https://doi.org/10.1080/07924259.2017.1311951>

Lopes D.F.C., Peixoto S.R.M., Frédou F.L., Silva E.F.B., 2014. Population biology of Seabob-shrimp *Xiphopenaeus kroyeri* (Heller, 1862) captured on the south coast of Pernambuco State, northeastern Brazil. *Braz. J. Oceanogr.* 62, 331–340. <https://doi.org/10.1590/S1679-87592014079706204>

Ministério da Pesca e Aquicultura (MPA), 2011. Boletim Estatístico da Pesca e Aquicultura. Ministério da Pesca e Aquicultura, Brasília. p. 129. https://www.icmbio.gov.br/cepsul/images/stories/biblioteca/download/estatistica/est_2011_bol__bra.pdf

Ohtomi J., Yamamoto S., 1997. Change in gonadosomatic index with ovarian maturation in jack-knife shrimp *Haliporoides sibogae* off southwestern Kyushu, Japan. *Fish Sci.* 63, 1044-1045. https://www.jstage.jst.go.jp/article/fishsci1994/63/6/63_6_1044/_pdf

Öndes F., Kaiser M.J., Murray L.G., 2017. Relative growth and size at onset of sexual maturity of the brown crab, *Cancer pagurus* in the Isle of Man, Irish Sea. *Mar Biol Res.* 13, 237–245. <https://doi.org/10.1080/17451000.2016.1248849>

Paschoal L.R.P., Guimarães F.J., Couto E.C.G., 2016. Growth and reproductive biology of the amphidromous shrimp *Palaemon pandaliformis* (Decapoda: Caridea) in a Neotropical River from northeastern Brazil. *Zoologia (Curitiba)*. 33, 06. <https://doi.org/10.1590/S1984-4689zool-20160060>

Peixoto S., Cavalli R.O., D’Incao F., Milach A.M., Wasielesky W., 2003. Ovarian maturation of wild *Farfantepenaeus paulensis* in relation to histological and visual changes. *Aquacult Res.* 34(14), 1255–1260. <https://doi.org/10.1046/j.1365-2109.2003.00933.x>

Peixoto S., Calazans N., Silva E.F., Nole L., Soares R., Frédo F.L., 2018. Reproductive cycle and size at first sexual maturity of the white shrimp *Litopenaeus schmitti* (Burkenroad, 1936) in northeastern Brazil. *Lat. Am. J. Aquat. Res.* 46(1), 1–9. <http://dx.doi.org/10.3856/vol46-issue1-fulltext-1>

Penn J.W., 1980. Spawning and fecundity of the western king prawn, *Penaeus latisulcatus* Kishinoue, in western Australian waters. *Aust. J. Mar. Freshwater Res.* 31, 21-35. <https://doi.org/10.1071/MF9800021>

Pérez-Farfante I., Kensley B.F., 1997. Penaeoid and sergestoid shrimps and prawns of the world: key and diagnoses for the families and genera. *Annales du Muséum National d’Histoire Naturelle. Muséum national d’Histoire naturelle, Paris*, 175, 233p. <https://sciencepress.mnhn.fr/en/collections/memoires-du-museum-national-d-histoire-naturelle/penaeids-and-sergestoid-shrimps-and-prawns-world>

Rahman M.M., Ohtomi J., 2017. Reproductive biology of the deep-water velvet shrimp *Metapenaeopsis sibogae* (De Man, 1907) (Decapoda: Penaeidae). *J. Crustac. Biol.* 37, 743–752. <https://doi.org/10.1093/jcbiol/rux084>

Rahman M.M., Ohtomi J., 2020. Ovarian maturation, size at sexual maturity and spawning season of *Metapenaeopsis provocatoria owstoni* Shinomiya & Sakai, 2000 (Decapoda: Penaeidae). *J. Crustac. Biol.* 49, 109–120. https://doi.org/10.18353/crustacea.49.0_109.

Reis Jr. J.J.C, Freire K.M.F., Rosa L.C., Barreto T.M.R.R., Pauly D., 2017. Population dynamics of Atlantic Seabob *Xiphopenaeus kroyeri* (Decapoda: Penaeidae) off the state of Sergipe, north-eastern Brazil. *J. Mar. Biolog. Assoc. U.K.* 1- 11. <https://doi.org/10.1017/S0025315417001916>

Sancinetti G.S., Azevedo A., Castilho A.L., Fransozo A., Costa R.C., 2015. Population biology of the commercially exploited shrimp *Artemesia longinaris* (Decapoda: Penaeidae) in an upwelling region in the Western Atlantic: comparisons at different latitudes. *Braz. J. Biol.* 75, 305–313. <https://dx.doi.org/10.1590/1519-6984.11813>

Sakaji H., 2001. Observations of the oocytes of the small penaeid shrimps *Metapenaeopsis aegyptia*, *M. barbata*, and *M. sinica*. *Benthos Res.* 56, 81–85. https://doi.org/10.5179/benthos1996.56.2_81

Sakaji H., Tsuchiya K., Segawa S., 2000. Oocyte development of *Metapenaeopsis dalei* (Penaeidae, Decapoda, Crustacea). *Invertebr. Reprod. Dev.* 38, 7–12. <https://doi.org/10.1080/07924259.2000.9652431>

Sastry A.N., 1983. Ecological aspects of reproduction. In: Vernberg, F.J.; Vernberg, W.B.; editors. *The biology of Crustacea*. New York (NY): Academic Press; p. 179–270.

Silva E.F., Calazans N., Nolé L., Castelo-Branco T., Soares R., Guerra M.M.P., Frédou F.L., Peixoto S., 2016. Reproductive dynamics of the southern pink shrimp *Farfantepenaeus subtilis* in northeastern Brazil. *Aquat Biol.* 25, 29–35. <https://doi.org/10.3354/ab00653>

Silva C.N.S., Broadhurst M.K., Medeiros R.P., Dias J.H., 2013. Resolving environmental issues in the southern Brazilian artisanal penaeid-trawl fishery through adaptive co-management. *Mar. Policy.* 42, 133-141. <https://doi.org/10.1016/j.marpol.2013.02.002>

Sokal R.R., Rohlf F.J., 1995. *Biometry The Principles and Practice of Statistics in Biological Research*. 3rd Edition, W.H. Freeman and Co., New York.

Tu C.Y., Chen K.T., Hsieh C.H., 2018. Fishing and temperature effects on the size structure of exploited fish stocks. *Sci Rep.* 8, 7132. <https://doi.org/10.1038/s41598-018-25403-x>

Vazzoler A.E., 1996. *Biologia da Reprodução de Peixes Teleósteos: Teoria e Prática*. Nupelia, Maringá-PR, 169p.

Wallace R., Selman K., 1981. Cellular and dynamic aspects of oocyte growth in teleosts. *Am. Zool.*, 21, 325-343. <https://www.jstor.org/stable/3882637>

Watters G., Hobday A.J., 1998. A new method for estimating the morphometric size at maturity of crabs. *Can. J. Fish. Aquat. Sci.* 55, 704–714. <https://doi.org/10.1139/f97-266>

Wenner A.M., 1972. Sex ratio as a function of size in marine Crustacea. *Am Nat.* 106, 321–350. <https://www.journals.uchicago.edu/doi/pdf/10.1086/282774>

Williams A.B., 1965. Marine decapod crustaceans of the Carolinas. U. S. Fish. Wildl. Serv. Fish. Bull. 65, 1–298. <http://garfield.library.upenn.edu/classics1983/A1983QK63400001.pdf>

Wilder M.N., Okumura T., Tsutsui N., 2010. Reproductive Mechanisms in Crustacea Focusing on Selected Prawn Species: Vitellogenin Structure, Processing and Synthetic Control. *Aqua-Bio. Sci. Monogr.* 3 (3), 73–110. <https://doi.org/10.5047/absm.2010.00303.0073>

Yano I., 1988. Oocyte development in the kuruma prawn *Peneaus japonicus*. *Mar Biol* 99: 547–553. <https://doi.org/10.1007/BF00392562>

Young C.L., Suthers I.M., Johnson D.D., Gray C.A., Ochwada-Doyle F.A., 2018. Don't Blame It on the Moonlight: Abiotic Drivers of Reproductive Development in an Estuarine-Dependent Prawn. *Estuaries Coast.* 41, 444–452. <https://doi.org/10.1007/s12237-017-0284-4>

4. Considerações Finais

As observações histológicas do desenvolvimento de ovócitos de *X. kroyeri* permitiu determinar pela primeira vez a oogênese em seis estágios distintos: ovócito cromatina nucleolar, ovócito cromatina perinucleolar, ovócito em vitelogênese primária, ovócito em vitelogênese secundária, ovócito maturo e ovócito atrésico. As observações histoquímicas sugerem um aumento progressivo das proteínas, polissacarídeos neutros e colágeno ocorre a partir dos ovócitos vitelogênicos até sua maturação final. Observamos vesículas compostas de colágeno e glicoproteínas por todo o citoplasma do ovócito maturo. As células foliculares formam uma camada externa ao redor dos ovócitos vitelogênicos e podem estar envolvidas na transferência de proteínas para as células germinativas.

Além disso, observamos que a abordagem dos diferentes métodos de identificação dos estágios maturacionais macroscópicos mostrou que ambos os métodos se apresentaram eficientes para identificar o estágio maturo, uma vez que 100% das amostras foram identificadas corretamente. O agrupamento dos estágios desovado e repouso em um único estágio pode acarretar em erros nas estimativas de época de desova, pois apresentam características e interpretações opostas do ponto de vista reprodutivo.

O *X. kroyeri* apresenta seis estágios de desenvolvimento ovariano baseados em características macroscópicas e histológicas: imaturo, em desenvolvimento inicial, em desenvolvimento avançado, maturo, desovado e repouso. A salinidade, temperatura e precipitação mostraram uma correlação significativa com o ciclo reprodutivo das fêmeas, que foi considerado sazonal, com uma porcentagem maior de fêmeas maduras de outubro a março (estação seca). A época de desova mais intensa ocorre durante o período de maior pluviosidade, com uma porcentagem maior de fêmeas em repouso. A observação das variáveis ambientais, estágios de desenvolvimento ovariano e época de desova sugere que tanto as fêmeas desovadas quanto as maduras devem ser monitoradas para estabelecer medidas de manejo para reprodutores. Os resultados obtidos na presente Tese contribuem para o aprimoramento das técnicas empregadas no manejo de reprodutores em cativeiro e para o estabelecimento de medidas de gestão para a pesca de camarões peneídeos.

5. Referências Bibliográficas

AYUB, Z.; AHMED, M. A. Description of the ovarian development stages of penaeid shrimp from the coast of Pakistan. **Aquaculture Research**, v. 33, p.767-776, 2002.

BARROS, L.C.; BARRETO, O.J.S.; HENRIQUES, M.B. The economic viability for the production of live baits of white shrimp (*Litopenaeus schmitti*) in recirculation culture system. **Aquac. Int.** 22, 1925–1935, 2014.

BOLOGNINI, L.; DONATO F.; LUCCHETTI A.; OLIVOTTO, I.; TRUZZI, C.; RANDAZZO, B.; ANTONUCCI, M.; ILLUMINATI, S.; GRATI, F. A multidisciplinary approach to study the reproductive biology of wild prawns. **Scientific Reports nature**, v. 7, 2017.

BOOS, H.; COSTA, R.C.; SANTOS, R.A.F.; DIAS-NETO, J.; SEVERINO-RODRIGUES, E.; RODRIGUES, L.F.; D'INCAO, F.; IVO, C.T.C.; COELHO, P.A. **Avaliação dos Camarões Peneídeos (Decapoda: Penaeidae)**. Cap. 23: p. 300-317; 2016.

CARVALHO-BATISTA, A.; TEROSSI, M.; ZARA, F.J.; MANTELATTO, F.L.; COSTA, R.C. A multigene and morphological analysis expands the diversity of the seabod shrimp *Xiphopenaeus Smith*, 1869 (Decapoda: Penaeidae), with descriptions of two new species. **Scientific Reports**, vol. 9, no. 15281, pp. 1-19, 2019.

COSTA R. C.; FRANSOZO A.; MELO G. A. S.; FREIRE F. A. M. Chave ilustrada para identificação dos camarões Dendrobranchiata do litoral norte do estado de São Paulo, Brasil. **Biota Neotropica**, v. 3, p. 1–12, 2003.

COSTA, R. C.; FRANSOZO, A.; FREIRE, F. A.; CASTILHO, A. L. Abundance and ecological distribution of the " sete-barbas" shrimp *Xiphopenaeus kroyeri* (Heller, 1862) (Decapoda: Penaeoidea) in three bays of the Ubatuba region, southeastern Brazil. *Gulf and Caribbean Research*, 19(1), 33-41, 2007.

CRAVEIRO, C.; SOARES, R.; CASTRO-NETO, H.; SILVA, E. F.; SOARES, A.; DE OLIVEIRA, P. G.; PEIXOTO, S. Ovarian maturation of *Penaeus subtilis* (Decapoda:

Penaeidae): A new insight to describe oocyte development and somatic structures. **Acta Zoologica**, 2022.

D'INCAO, F. Subordem Dendrobranchiata (camarões marinhos). Pp. 271-299 In Buckup, L. and Bond-Buckup, G. (eds.). **Os camarões do Rio Grande do Sul**. Editora da Universidade UFRGS, Porto Alegre, 1999.

FAO. **The world state of fisheries and aquaculture 2014**. FAO Fisheries and Aquaculture Department, Rome, 2016, p.204, 2014.

FAO. **The State of World Fisheries and Aquaculture 2016**. Contributing to food security and nutrition for all. Rome. 200 pp, 2016.

FAO. **The State of World Fisheries and Aquaculture 2022**. Towards Blue Transformation. Rome, FAO, 2022.

FLOR, H. R.; OSHIRO, L. M.Y.; COSTA, T. V.; FUGIMURA, M. M. S.; RODRIGES, F. N. G.; MATTOS, L. A. Efeito da proporção sexual sobre o desempenho reprodutivo do camarão-rosa *Farfantepenaeus brasiliensis* (Decapoda: Penaeoidea). **Boletim do Instituto de Pesca (Online)**, v. 42, p. 343-351, 2016.

FREIRE, K.M.F.; TUBINO, R.A.; MONTEIRO-NETO, C.; ANDRADE-TUBINO, M.F.; BELRUSS, C.G.; TOMAS, A.R.G.; TUTUI, S.L.S.; CASTRO, P.M.G.; MARUYAMA, L.S.; CATELLA, A.C.; CREPALDI, D.V.; DANIEL, C.R.A.; MACHADO, M.L.; MENDONÇA, J.T.; MORO, P.S.; MOTTA, F. S.; RAMIRES, M.; SILVA, M.H.C.; VIEIRA, J.P. Brazilian recreational fisheries: current status, challenges and future direction. **Fish. Manag. Ecol.** 23, 276–290, 2016.

GARCIA, R.C.P.; CRAVEIRO, C.F.F.; BERNABE, C.V.; SILVA, M.A.; ARIDE, P.H.R.; OLIVEIRA, A.T.; GONÇALVES, F.R.S.C.; SANTANDER-NETO, J., LAVANDER, H.D.; FAGGIO, C. Gonadal development of females of the white shrimp *Penaeus schmitti* (Burkenroad, 1936) caught in southeastern Brazil. **J. Mar. Sci. Eng.** 29, 653, 2021.

GILLETT, R. Global study of shrimp fisheries. **FAO Document technique sur les peches**. no. 475. Rome: FAO. 331 p, 2008.

HENRIQUES, B.M.; FAGUNDES, L.; PETESSE, M.L.; DA SILVA, N.J.R.; REZENDE, K.F.O.; BARBIERI, E. Lambari fish *Deuterodon iguape* as an alternative to live bait for estuarine recreational fishing. **Fish. Manag. Ecol.** 25, 400–407, 2018.

HOLTHUIS, L.B. Shrimp and prawns of the world. An annotated catalogue of species of interest to fisheries. **FAO Species Catalogue**, Roma, 1: 1-261, 1980.

JENSEN, L.; FURTADO, P.S.; FUGIMURA, M.M.; GARCIA, L.O.; POERSCH, L.H.; VERANI, J.R.; WASIELESKY, W. The effect of stocking density on the transport of pink shrimp *Farfantepenaeus brasiliensis* (Crustacea: Decapoda), as live bait for sport fishing in Brazil. *Lat. Am. J. Aquat. Res.* 42, 204–212, 2014.

LOPES, D. F. C.; PEIXOTO, S.; FRÉDOU, F. L. Population biology of seabob-shrimp *Xiphopenaeus kroyeri* (Heller, 1862) captured on the south coast of Pernambuco State, northeastern Brazil. *Braz. J. Oceanogr.*, v. 62, p. 331-340, 2014.

MAPA, Ministério da Agricultura e Pecuária. **Consumo e tipos de peixes no Brasil, 2021.** Acesso em 25 de janeiro de 2022. disponível em <https://www.gov.br/agricultura/pt-br/assuntos/aquicultura-e-pesca/rede-do-pescado/consumo-e-tipos-de-peixes-no-brasil>

MPA, Ministério da Pesca e Aquicultura. **Boletim estatístico da pesca e aquicultura 2011**, 2011.

PEIXOTO, S.; CAVALLI, R. O.; D'INCAO, F.; MILACH, Â. M.; WASIELESKY, W. Ovarian maturation of wild *Farfantepenaeus paulensis* in relation to histological and visual changes. **Aquaculture Research**, 34(14), 1255-1260, 2003.

PEIXOTO, S.; CALAZANS, N.; SILVA, E. F.; NOLE, L.; SOARES, R.; FREDOU, F. L. Reproductive cycle and size at first sexual maturity of the white shrimp *Litopenaeus schmitti* (Burkenroad, 1936) in northeastern Brazil. **Latin American Journal of Aquatic Research**, v. 46, n. 1, p. 1-9, 2018.

PEIXOTO, S.; CAVALLI, R.; KRUMMENAUER, D.; WASIELESKY, W.; D'INCAO, F. Influence of artificial insemination on the reproductive performance of *Farfantepenaeus paulensis* in conventional and unisex maturation system. **Aquaculture**, v. 230, p. 197-204, 2004.

PEIXOTO, S.; CAVALLI, R.O.; D'INCAO, F.; WASIELESKY, W.; AGUADO, N. Description of reproductive performance and ovarian histology of wild *Farfantepenaeus paulensis* from shallow waters in southern Brazil. **Nauplius**, v. 10, p. 149-153, 2002.

PEREZ FARFANTE, I. S. A. B. E. L.; KENSLEY, B. Penaeoid and sergestoid shrimps and prawns of the world. Keys and diagnoses for the families and genera. **Editions du Museum national d'Histoire naturelle**, 1997.

PRETO, A.L.; PISSETI, T.L.; WASIELESKY, W.J.; POERSCH, L.H.; CAVALLI, R.O. Production of live bait-shrimp (*Farfantepenaeus paulensis*) in cages at varying stoking densities. **Bol. Inst. Pesca**, 35, 39–45, 2009.

QUINTERO, M.E.S.; GRACIA, A. Stages of gonadal development in the spotted pink shrimp *Penaeus brasiliensis*. **J. Crustac. Biol.** 18 (4), 680–685, 1998.

RIOS, A.S.; SHINOZAKI-MENDES, R.A.; SANTANA, J.L.; SOUZA-FILHO, J.F. Ovarian development of the crab *Eriphia gonagra* (Fabricius, 1981) (Decapoda: Brachyura: Eriphiidae) in northeastern Brazil. **Journal of Crustacean Biology**, vol. 42, no. 1, pp. 1-11, 2022. <https://doi.org/10.1093/jcbiol/ruac040>.

SILVA, S. L. R. Biologia reprodutiva e crescimento de camarões marinhos (Decapoda: Penaeidae) na plataforma continental de Sergipe. 2016. 109 p. **Dissertação (Mestrado)** - Universidade Federal de Sergipe, São Cristóvão, Brasil.

SIMÕES, M.S.; HECKLER, G.S.; COSTA, R.C. Reproductive period and recruitment of Penaeoidea shrimp on the southeastern Brazilian coast: implications for the closed season. **Crustaceana**, 90, 1177–1192, 2017.

SIMPSON, A. W.; WATLING, L. An investigation of the cumulative impacts of shrimp trawling on mud-bottom fishing grounds in the Gulf of Maine: effects on habitat and

macrofaunal community structure. **Journal of Marine Science**, v. 63, p. 1616-1630, 2006.

VALENTI, W.C.; HAYD, L.A.; VETORELLI, M.P.; MARTINS, M.I.E.G. Economic analysis of amazon river prawn farming to the markets for live bait and juveniles in Pantanal, **Brazil. Bol. Inst. Pesca**, 37 (2), 165–176, 2011.

WILLIAMS, A.B. Marine decapod crustaceans of the Carolinas. U. S. Fish. Wildl. Serv. **Fish. Bull.** 65, 1–298, 1965.